

Case report

Carotid-cavernous fistula with secondary ocular hypertension. A case report

DOI: 10.5377/alerta.v7i2.17067

Daniel Benjamín Mejía Llanes

Ophthalmological Service, Medical Specialties Clinic, Salvadoran Social Security Institute (ISSS). San Salvador, El Salvador.

Correspondence

✉ db.mejia@outlook.com

ORCID 0009-0006-7458-6149

OPEN ACCESS

Fístula carótido-cavernosa con hipertensión ocular secundaria: reporte de caso

Suggested citation:

Mejía Llanes DB. Carotid-cavernous fistula with secondary ocular hypertension. A case report. *Alerta*. 2024;7(2):138-145. DOI: 10.5377/alerta.v7i2.17067

Editor:

Larisa Chavarría.

Received:

October 2, 2023.

Accepted:

May 6, 2024.

Published:

July 24, 2024.

Author contribution:

DBML: study conception, manuscript design, data collection and management or software, writing, revising, and editing.

Conflicts of interest:

The author declared there are not conflicts of interest.



© 2024 by the author. This is an open access article distributed under the terms and conditions of the Creative Commons Attribution (CC BY) license (<https://creativecommons.org/licenses/by/4.0/>).

Abstract

Case presentation. 62 years old female with ten months history of ocular pain, proptosis, and conjunctival hyperemia in left eye, developing swollen upper eyelid. Best corrected visual acuity was 20/30 in her left eye, with and intraocular pressure of 30 mmHg. **Treatment.** Nuclear magnetic resonance of the orbits showed proptosis and dilated superior ophthalmic vein. Initial diagnosis. Abnormal venous drainage and ocular hypertension in the left eye. Topical hypotensive treatment of the left eye was initiated with ocular hypotensive eyedrops. Angiotomography of the orbit and left eye Doppler ultrasound, with upper eyelid emphasis, gave visualization of high flow carotid-cavernous fistula. Cerebral diagnostic and therapeutic angiography with embolization of the fistula in middle meningeal and ascending pharyngeal arteries showed no vascular flow after the procedure. **Outcome.** Positive clinical outcome, with corrected visual acuity conserved and normal eye pressure. Notable relief of ocular congestion and swollen upper eyelid with no proptosis in the left eye. Doppler ultrasound in the upper eyelid showed normal flow rate measurement.

Keywords

Carotid-Cavernous Fistula, Ocular Hypertension, Antiglaucoma Agents.

Resumen

Presentación del caso. Paciente femenina de 62 años con una historia de diez meses de dolor ocular pulsátil, proptosis e inyección conjuntival en el ojo izquierdo; posteriormente presentó un edema palpebral superior izquierdo. Se evaluó con mejor agudeza visual corregida de 20/30 en dicho ojo y presión intraocular de 30 mmHg. **Intervención terapéutica.** Resonancia magnética nuclear de órbitas evidencia proptosis y dilatación de vena oftálmica superior izquierda, por lo que se diagnosticó como defecto del drenaje venoso e hipertensión ocular del ojo izquierdo. Inició tratamiento hipotensor tópico de ojo izquierdo; estudios de imagen angiotomografía de órbitas y ultrasonido doppler de ojo izquierdo, con énfasis en párpado superior, evidencian fístula carótido-cavernosa izquierda de alto gasto. Se realizó angiografía cerebral diagnóstica y terapéutica con embolización de fístula en arterias meníngea media y faríngea ascendente con ausencia de flujo por dichas ramas después de la intervención. **Evolución clínica.** Presentó una evaluación clínica favorable, conservando agudeza visual y presión intraocular dentro de valores normales en ojo izquierdo, con evidente disminución de congestión venosa episcleral, edema de párpado superior y ausencia de proptosis izquierda. Ultrasonido doppler control de párpado superior izquierdo con disminución de flujo venoso a valores normales.

Palabras clave

Fístula carótido-cavernosa, hipertensión ocular, agentes antiglaucoma.

Introduction

An arteriovenous fistula is a lesion resulting from an abnormal communication between arterial and venous flow through a capillary

bed.ⁱ It has many causes, including trauma or degeneration. Arteriovenous fistulas are classified as direct and indirect.ⁱⁱ An incidence of 0.2 % has been reported in patients with brain trauma and up to 4 % in cases with skull base fracture.ⁱⁱⁱ

Direct carotid-cavernous fistulas are defined by high vascular flow, with direct communication between the internal carotid artery and the cavernous sinus; trauma is the most frequent cause.^{iv} They may also be caused by rupture of aneurysms in the internal carotid artery in the cavernous sinus, Ehlers-Danlos syndrome type IV, or as a result of iatrogenic factors during neuroradiological or surgical interventions.

Indirect low-output carotid-cavernous fistulas are the consequence of communication between the meningeal branches of the internal or external carotid artery and the cavernous sinus; they are associated with degenerative processes in older patients with arterial hypertension, vascular pathologies, or atherosclerosis. Other causes may be fibromuscular dysplasia, Ehlers-Danlos syndrome type IV,^v and internal carotid artery dissection.

There is also the Barrow classification based on angiographic criteria related to direct carotid-cavernous fistula. Barrow A, when there is a direct connection between the internal common carotid artery and the cavernous sinus; Barrow B when there is indirect communication between the meningeal branches of the internal carotid artery and the cavernous sinus; Barrow C, if the communication is indirect between the branches of the external carotid artery and the cavernous sinus; and Barrow D, if the communication is indirect between the meningeal branches of the internal and external carotid artery.^{vi}

Direct fistulas manifest with episcleral vascular tortuosity, pulsatile proptosis, and audible ocular murmur.^{vii} Because of the associated anomalous vascular flow, it can result in ocular ischemic damage by shunting arterial blood into the venous system, resulting in venous drainage obstruction due to increased vascular resistance.^{viii} The resulting increase in intraocular pressure may cause glaucomatous optic neuropathy,^{ix,x} choroidal effusion, non-granulomatous anterior uveitis, or damage to cranial nerves II, IV, or VI, by congestion in the orbit, or increased pressure in the cavernous sinus.^{xi} On the contrary, indirect fistulas present less vascular flow than direct fistulas; their clinical presentation may be insidious, with less orbital congestion and chronic red eye due to arterialization of conjunctival vessels. Increased episcleral venous pressure may result in elevated intraocular pressure,ⁱⁱⁱ with a similar risk of glaucomatous damage to the optic nerve.

Among the complementary studies, angio-resonance can be of diagnostic help; however, digital cerebral angiography is the

most sensitive procedure for diagnosis, since it allows the definition of the anatomy of the fistula, type of blood flow, collateral circulation, and therapeutic surgical strategy.^{vii}

The treatment of carotid-cavernous fistula is interdisciplinary and individualized.^{ixiii} Indirect fistulas may resolve spontaneously; therefore, conservative management, applying direct pressure on the eyeball or internal carotid compression with the contralateral hand, is recommended. A more aggressive approach is made based on the patient's clinical evolution. Endovascular intervention in direct fistulas is performed with detachable balloons and stents for larger fistulas, liquid embolic agents, and coil wires for smaller ones through transarterial access.^{xiii-xv} En algunas ocasiones, puede valorarse el abordaje venoso central o periférico. For some cases, a central or peripheral venous approach must be considered. Additionally, venous access through orbitotomy has been reported.^{xvi}

Additionally, to each case accordingly, it is important to control intraocular pressure with antiglaucomatous medications^{vi} to prevent secondary glaucomatous neuropathy.

The differential diagnosis is varied. The following are considered among them: cavernous sinus thrombosis, retrobulbar hemorrhage secondary to traumatism, thyroid orbitopathy, orbital vasculitis, sarcoidosis, infections, benign or malignant tumors, and metastasis in the orbit.ⁱ

Case presentation

This is a 62-year-old woman who consulted with a ten-month history of mild to moderate pulsatile left eye pain, with foreign body sensation, conjunctival injection, and sporadic epiphora, accompanied by four months of noticing a progressive, pulsatile, slightly mobile, and non-painful tumor in the inner third of the left upper eyelid. The patient reported a medical history of arterial hypertension and denied trauma or other medical or surgical history.

Physical examination identified best corrected visual acuity of 20/30 in the right eye and 20/25 in the left eye. Exophthalmometry at an interorbital distance of 106 mm, degree of ocular prominence of 18 mm in the right eye, and 22 mm in the left eye with evident left proptosis. Extraocular movements were preserved.

In addition, pulsation of the eyeball was palpated, and the ocular murmur was auscultated (Dandy's triad). Mild ptosis edema, pulsatile and non-painful in the left upper eyelid, was evaluated. In the slit lamp, the measure of the intraocular pressure was 20 mmHg in the right eye and 30 mmHg in the left eye. Similarly,

superior episcleral and nasal vascular congestion (Figure 1) and inferior chemosis were identified. Fundoscopy of the left eye showed mild dilatation and tortuosity of the superior and inferior temporal venous vessels (Figure 2).

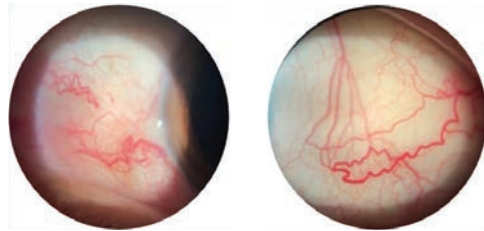


Figure 1. Slit lamp evaluation left eye

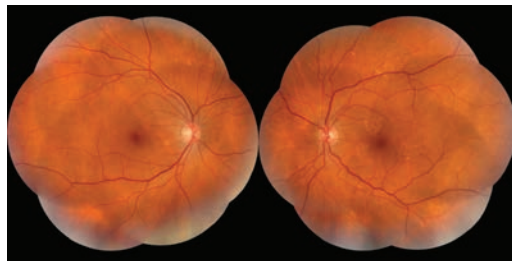


Figure 2. Fundoscopy of both eyes

Therapeutic intervention

Treatment was initiated with a topical hypotensive with timolol 0.5 %, dorzolamide 2 %, and brimonidine 0.2 % every 12 hours in the left eye. In addition, ophthalmologic studies

of optic nerve and ganglion cell optical coherence tomography, 24:2 campimetry in both eyes and magnetic resonance imaging of orbits and brain were indicated.

The MRI of orbits performed on the same consultation day reported proptosis and dilatation of the left superior ophthalmic vein (Figure 3).

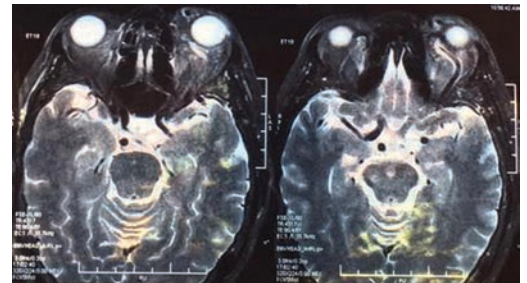


Figure 3. Magnetic resonance of orbits and brain

Optical coherence tomography of the optic nerve showed that the thickness and number of nerve fibers in both eyes were within the normal range, with 80 % symmetry. The cup/disc ratio was symmetrical, within normal mean in both eyes; a decrease in neuroretinal rim thickness was not reported. The thickness of ganglion cells in the macula was within normal values (Figure 4).

The result of the 24:2 campimetry of both eyes showed a nasal and temporal step in the

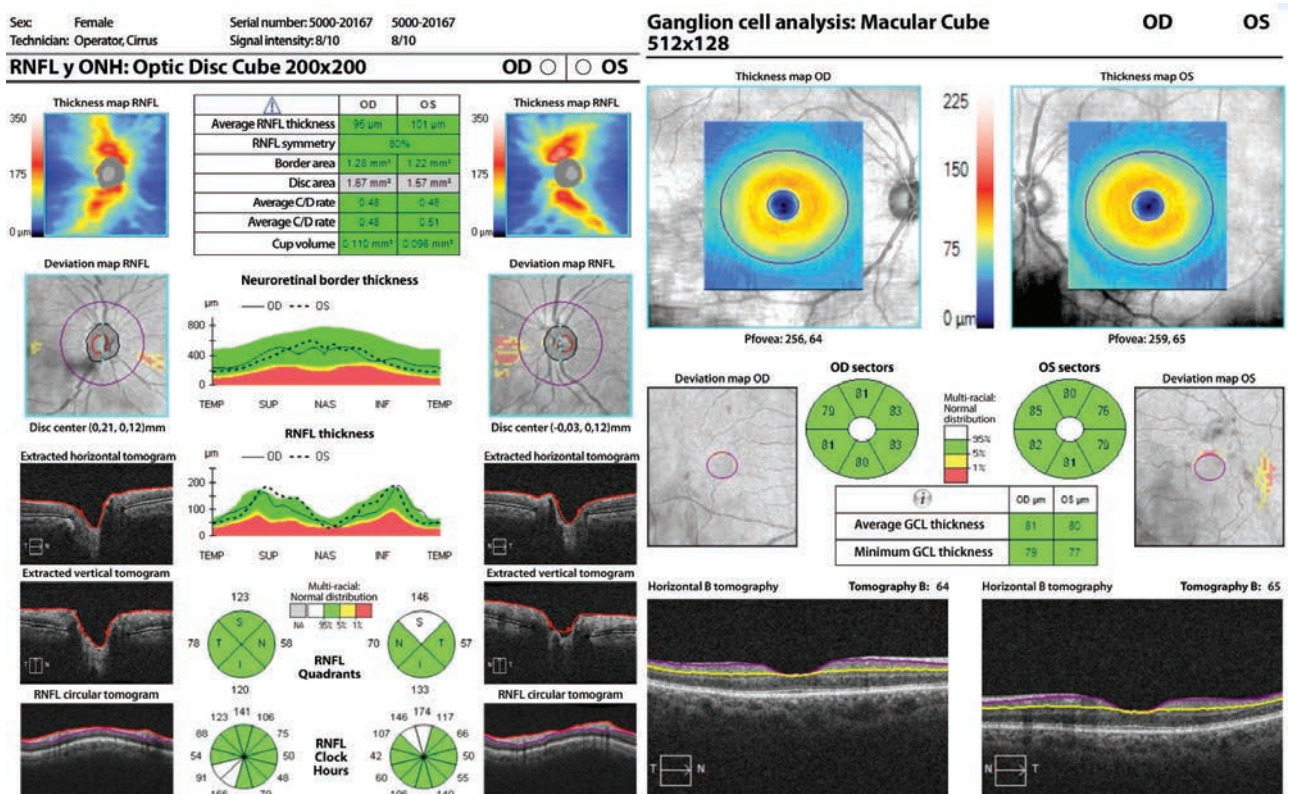


Figure 4. Optical coherence tomography of optic nerve and ganglion cells both eyes

left visual field (Figure 5); however, it presented 11 % of false negative errors and 1 % of false positive errors with a time duration of six minutes for SITA-Standard strategy; therefore, the interpretation was as inconclusive.

On the other hand, a venous drainage defect was identified in the left eye, consequently, an angio-tomography of orbits and brain was performed after 15 days, which showed a left carotid-cavernous fistula with the presence of arterial blood in the venous phase at the level of the cavernous sinus and vascular congestion in the superior ophthalmic vein (Figure 6).

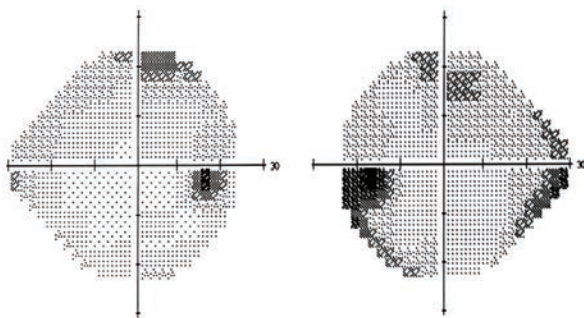


Figure 5. Campimetry 24:2 both eyes

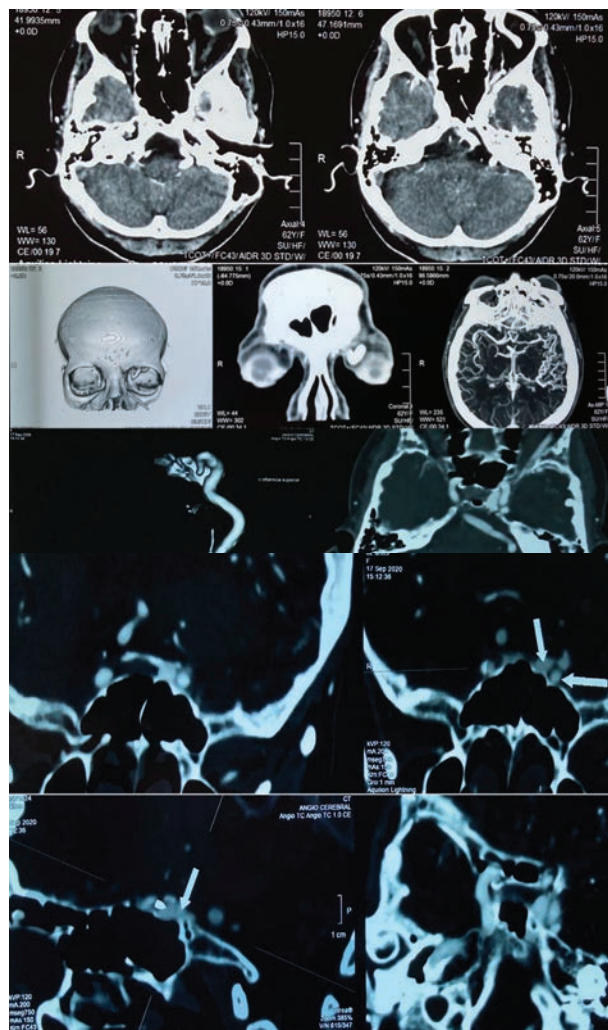


Figure 6. Cerebral angio-tomography of orbits and brain

After a month, a venous Doppler ultrasound of the upper eyelid was performed, which showed a venous vascular dilatation in the left upper eyelid. The ophthalmic veins presented a high vascular flow of 27 and 18 cm/s (Figure 7), which indicated a high-expenditure carotid-cavernous fistula. Moreover, cerebral magnetic angio-resonance imaging showed greater detail on the collateral circulation of the cavernous fistula (Figure 8).

After six months, diagnostic and therapeutic cerebral angiography was conducted through the right femoral artery approach using the Seldinger technique. During this procedure,

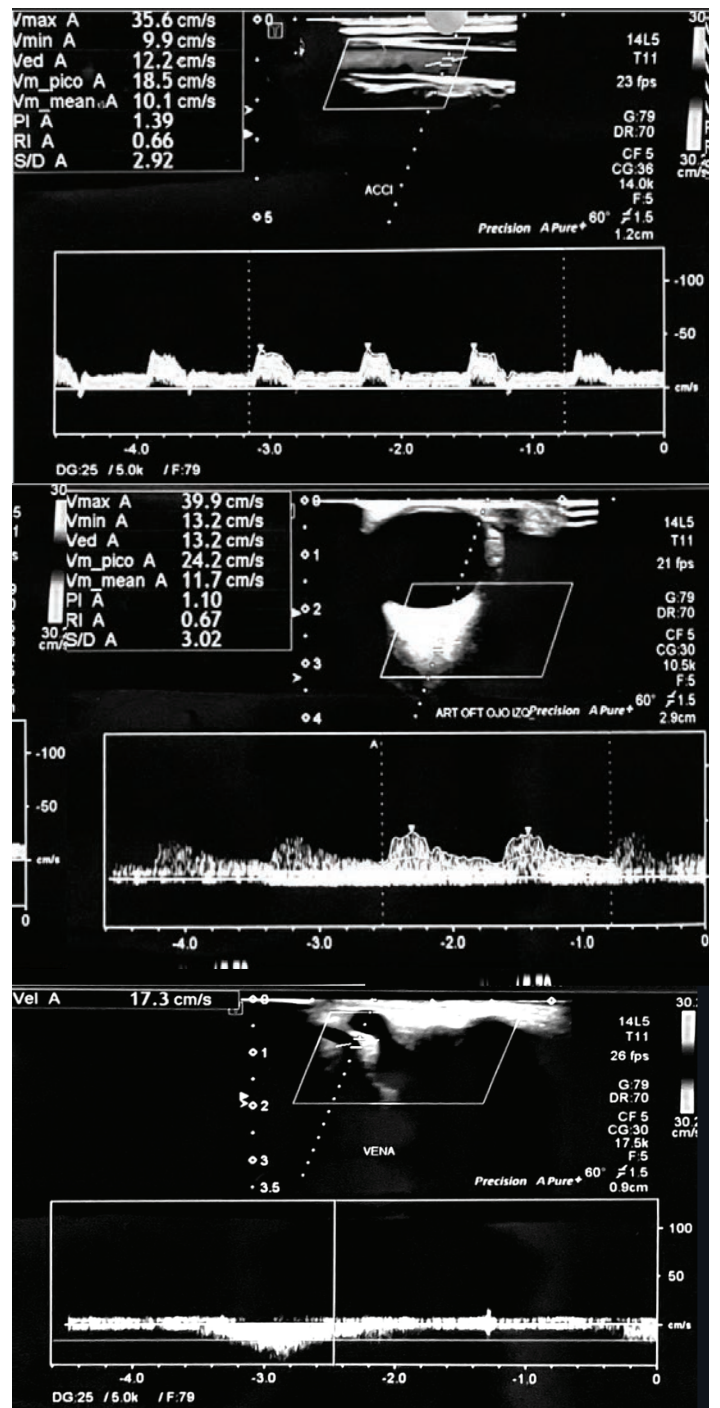


Figure 7. Venous doppler ultrasound of left upper eyelid

an anatomical defect of the "bovine" aortic arch was identified (Figure 9A), and a fistula with afferents to the middle meningeal artery (internal maxillary artery branch) and ascending pharyngeal artery with drainage to the left cavernous sinus (Figure 9B). An embolization with Coils and Onyx® was performed in the internal maxillary artery, and the Cosmos 10 3D 0.5 x 22 cm, the Hidrosoft Helical 10 0.5 x 15 cm,

and then 1 mL of Onyx® were placed; finally, the absence of flow in the branches (middle meningeal and superior pharyngeal) was assessed (Figure 9C and D).

Outcome

The clinical evolution was satisfactory, with a best corrected visual acuity of 20/25 in

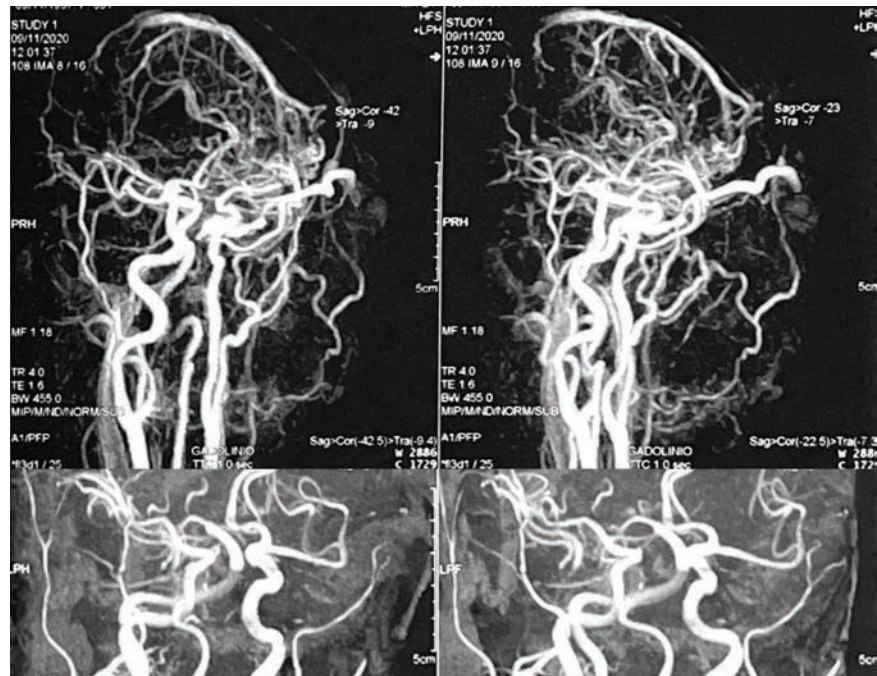


Figure 8. Cerebral magnetic resonance angiography

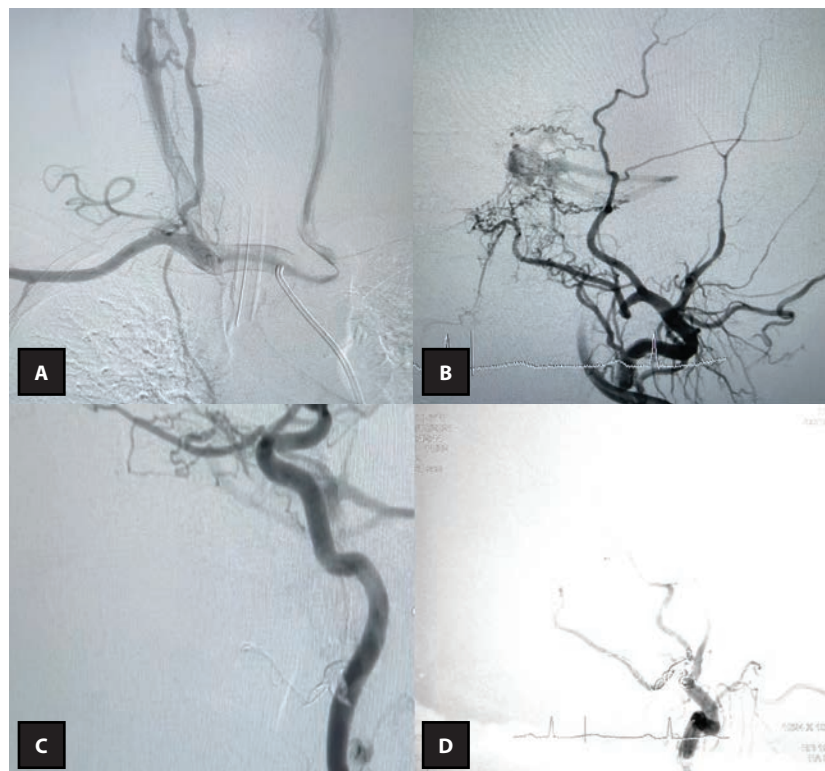


Figure 9. Diagnostic and therapeutic cerebral angiography. A. Bovine" aortic arch defect. B. Diagnostic cerebral angiography. C. and D. Therapeutic cerebral angiography (post-procedure)

the left eye; in addition, intraocular pressure was 17 mmHg, within normal values, and with an evident decrease in episcleral venous congestion (Figure 10) and edema of the left upper eyelid. Exophthalmometry performed at an interorbital distance of 106 mm with a prominence measurement of 18 mm for both eyes indicated an improvement in the initial proptosis of the left eye. Venous Doppler ultrasonography of the control left upper eyelid reported a flow of 2.6 to 3.1 cm/s, in the expected values of palpebral venous flow.

On the other hand, in the optical coherence tomography analysis study of the optic nerve and ganglion cells after treatment,

there was no evidence of progression in the damage of the optic disc or ganglion cells (Figure 11), preventing damage secondary to the initial ocular hypertension.

Clinical diagnosis

Left carotid-cavernous fistula with high output and secondary ocular hypertension in the left eye.

Discussion

Timely clinical diagnosis, through complementary imaging studies, is essential to reduce the complications associated

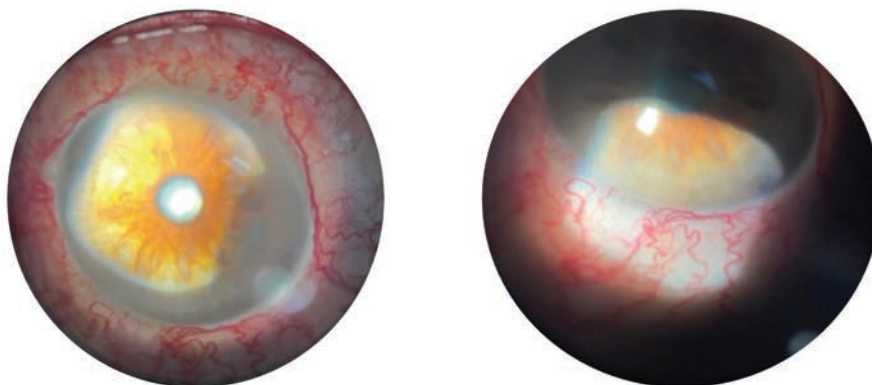


Figure 10. Slit-lamp evaluation of the left eye, post-treatment

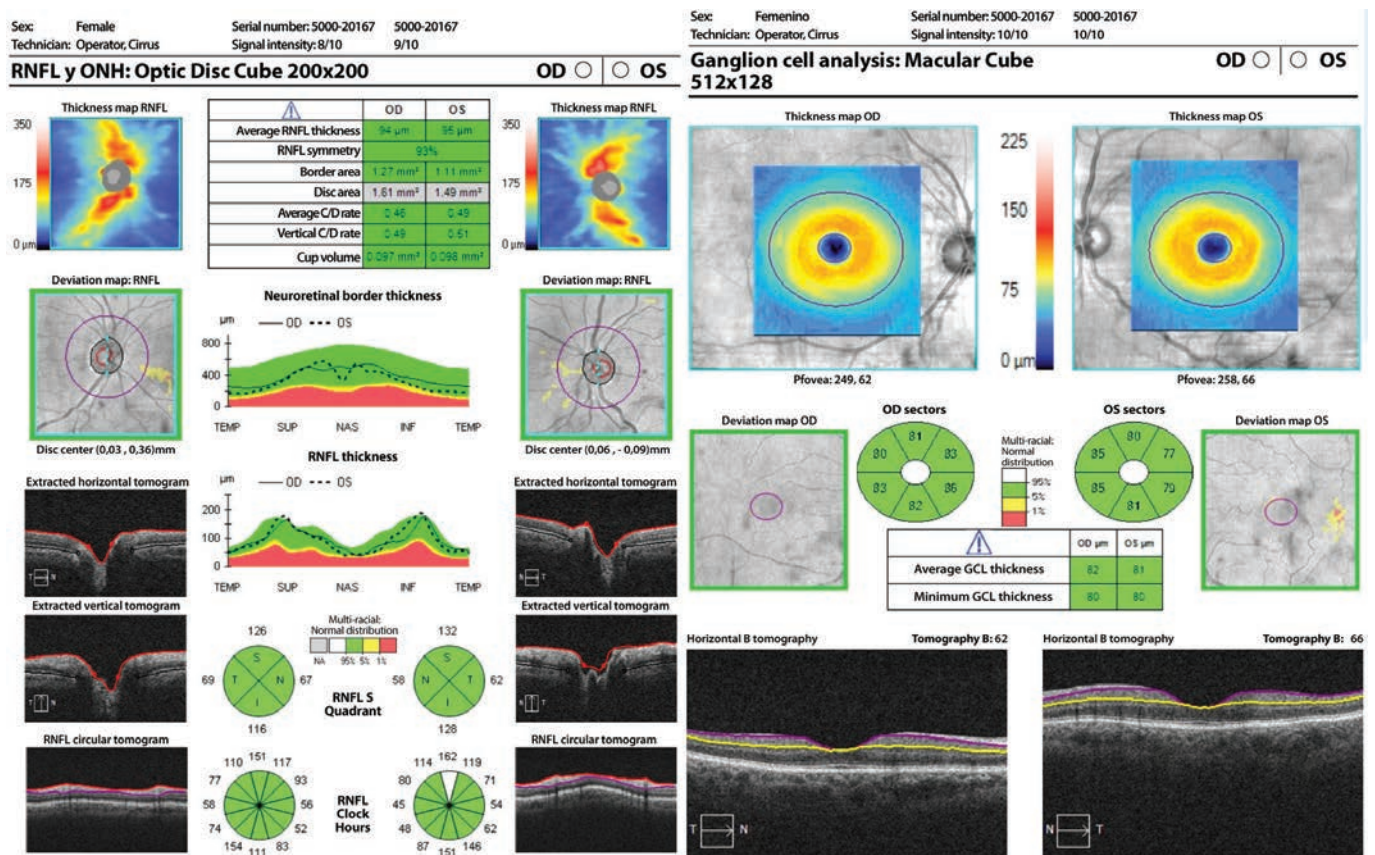


Figure 11. Optical coherence tomography of optic nerve and ganglion cells in both eyes, post left treatment

with ocular hypertension secondary to increased episcleral venous flow resistance in the carotid-cavernous fistula, with greater emphasis on the associated visual sequelae. The clinical features manifested as a high-output fistula, evidenced in imaging studies and the vascular flow velocity of the left upper eyelid; however, the vascular defect shown in the diagnostic cerebral angiography corresponds to that of an indirect Barrow C fistula, as it is associated with communication of branches of the external carotid artery and the cavernous sinus. However, some communication by meningeal branches of the internal carotid artery, associated with an indirect fistula type D, can be evidenced.^{vi}

On the other hand, it is recommended to consider the venous approach for the left internal carotid artery afferents, thus avoiding late recanalization. Likewise, diagnostic imaging and treatment through cerebral angiographic embolization is the mainstay of treatment of this pathology,ⁱⁱ which allows preservation of visual acuity and avoids neurological sequelae in other pairs of cranial nerves.^{iv} Similarly, topical hypotensive treatment provides a protective approach to the optic nerve, reducing ocular hypertension secondary to arteriovenous fistula.^{ix}

In this case, best corrected visual acuity was preserved, with intraocular pressure within normal values; after treatment, there was no evidence of secondary glaucomatous optic neuropathy. A multidisciplinary approach is necessary for the management and follow up of the clinical evolution to achieve favorable treatment results and resolve the clinical condition.^{xiii-xv}

Ethical aspects

The Declaration of Helsinki 2013 was complied with, keeping the patient's data confidential as the affiliation number. The clinical case is governed by the ethical principles of non-maleficence, justice, beneficence, and autonomy. The patient is aware of the public presentation of her clinical case through informed consent.

Acknowledgements

To Luis Edgardo Piche Lozano, Ophthalmology Specialty Coordinator and Alexis Castro Pérez, Chief of the Ophthalmology Service for their support in the analysis of this case. To José Roberto Corvera Urquilla, neuro-radiologist, chief of the Radiology Service of the Medical Specialty Clinic of the Salvadorean Social Security Institute for the interpretation of the imaging studies, and

to Cándido Omar Ortiz Vásquez and Dania Elizabeth Trinidad Arévalo, neurosurgeons and neuro-interventionists. All from the Salvadorean Social Security Institute.

Funding

Institutional support from the Salvadorean Social Security Institute for complementary imaging studies, as well as pharmacological treatment and endovascular intervention procedures.

References

- i. Bobby S. Korn. 2022-2023 Basic and Clinical Science Course, Section 07: Oculofacial Plastic and Orbital Surgery print 7°. San Francisco: American Academy of Ophthalmology; 2022. 377p.
- ii. Stacey AW, Gemmete JJ, Kahana A. Management of Orbital and Periocular Vascular Anomalies. *Ophthalm. Plast. Reconstr. Surg.* 2015;31(6):427-436. DOI: [10.1097/IOP.0000000000000504](https://doi.org/10.1097/IOP.0000000000000504)
- iii. Liang W, Xiaofeng Y, Weiguo L, Wusi Q, Gang S, Xuesheng Z. Traumatic Carotid Cavernous Fistula Accompanying Basilar Skull Fracture: a Study on the Incidence of Traumatic Carotid Cavernous Fistula in the Patients With Basilar Skull Fracture and the Prognostic Analysis About Traumatic Carotid Cavernous Fistula. *J. Trauma Inj. Infect. Crit. Care.* 2007;63(5):1014-1020. DOI: [10.1097/TA.0b013e318154c9fb](https://doi.org/10.1097/TA.0b013e318154c9fb)
- iv. Hamedani H, Hellmann D, Boyce W, Alesio ND. Traumatic carotid-cavernous fistula: A case report. *Radiol. Case Rep.* 2022;17(6):1955-1958. DOI: [10.1016/j.radcr.2022.02.065](https://doi.org/10.1016/j.radcr.2022.02.065)
- v. Henrard C, Belge H, Fastré S, Di Monaco S, Revencu N, Hammer F, *et al.* Cervical artery dissection: fibromuscular dysplasia versus vascular Ehlers-Danlos syndrome. *Blood Press.* 2019;28(2):139-143. DOI: [10.1080/08037051.2018.1557507](https://doi.org/10.1080/08037051.2018.1557507)
- vi. Barrow DL, Spector RH, Braun IF, Landman JA, Tindall SC, Tindall GT. Classification and treatment of spontaneous carotid-cavernous sinus fistulas. *J. Neurosurg.* 1985;62(2):248-256. DOI: [10.3171/jns.1985.62.2.0248](https://doi.org/10.3171/jns.1985.62.2.0248)
- vii. Sarkis Y, Worden A, Schreiber T, Lapitz A. High index of suspicion: diagnosing a carotid-cavernous fistula. *BMJ Case Rep.* 2023;16(3):e253473. DOI: [10.1136/bcr-2022-253473](https://doi.org/10.1136/bcr-2022-253473)
- viii. Chiu Y-J, Shih Y-J, Lee W-J, Liu Y-C. A man with proptosis of the left eye. *Ann. Emerg. Med.* 2022;80(5):420-455. DOI: [10.1016/j.annemergmed.2022.04.013](https://doi.org/10.1016/j.annemergmed.2022.04.013)

- ix. Kang JM, Tanna AP. Glaucoma. *Med. Clin. North Am.* 2021;105(3):493-510. DOI: [10.1016/j.mcna.2021.01.004](https://doi.org/10.1016/j.mcna.2021.01.004)
- x. Xia Y. A red eye induced by a spontaneous carotid cavernous fistula. *Am. J. Emerg. Med.* 2018;36(12):2336.e1-2336.e2. DOI: [10.1016/j.ajem.2018.08.055](https://doi.org/10.1016/j.ajem.2018.08.055)
- xi. Li S, Feng B, Feng Y, Pang Z, Lin Y. Carotid-cavernous fistula(CCF) presenting as paroxysmal painful ophthalmoplegia. *BMC Ophthalmol.* 2019;19(1):48. DOI: [10.1186/s12886-019-1039-8](https://doi.org/10.1186/s12886-019-1039-8)
- xii. Adam CR, Shields CL, Gutman J, Kim HJ, Hayek B, Shore JW, *et al.* Dilated Superior Ophthalmic Vein: Clinical and Radiographic Features of 113 Cases. *Ophthal. Plast. Reconstr. Surg.* 2018;34(1):68-73. DOI: [10.1097/IOP.0000000000000872](https://doi.org/10.1097/IOP.0000000000000872)
- xiii. Xinxing L, Jihui Z. Clinical Research of Combined Arteriovenous Approach Embolization on Complex Carotid-Cavernous Fistulas Liu J, editor. *BioMed Res. Int.* 2021;2021:1-5. DOI: [10.1155/2021/5580957](https://doi.org/10.1155/2021/5580957)
- xiv. Holland LJ, Mitchell Ranzcr K, Harrison JD, Brauchli D, Wong Y, Sullivan TJ. Endovascular treatment of carotid-cavernous sinus fistulas: ophthalmic and visual outcomes. *Orbit.* 2019;38(4):290-299. DOI: [10.1080/01676830.2018.1544261](https://doi.org/10.1080/01676830.2018.1544261)
- xv. Alexander MD, Halbach VV, Hallam DK, Cooke DL, Ghodke BV, Dowd CF, *et al.* Long-Term Outcomes of Endovascular Treatment of Indirect Carotid Cavernous Fistulae: Superior Efficacy, Safety, and Durability of Transvenous Coiling Over Other Techniques. *Neurosurgery.* 2019;85(1):E94-E100. DOI: [10.1093/neuros/nyy486](https://doi.org/10.1093/neuros/nyy486)
- xvi. Heran MKS, Volders D, Haw C, Shewchuk JR. Imaging-Guided Superior Ophthalmic Vein Access for Embolization of Dural Carotid Cavernous Fistulas: Report of 20 Cases and Review of the Literature. *Am. J. Neuroradiol.* 2019 40(4):699-702. DOI: [10.3174/ajnr.A5994](https://doi.org/10.3174/ajnr.A5994)