

Metachronous liver metastasis from a solid pseudopapillary pancreas tumor

DOI: 10.5377/alerta.v7i2.17065

Julio Cesar Alfaro Varela^{1*}, Mario Francisco Interiano Tobar², Glenda Estefanía Álvarez Salazar³

1-3. Hepato-Pancreato-Biliary Surgery Clinic; Medical, Surgical, and Oncology Hospital of Salvadoran Social Security Institute, San Salvador, El Salvador.

*Correspondence

✉ drjulioalfaro@hotmail.com

1.  0000-0003-4978-9754

2.  0000-0002-1930-5643

3.  0009-0000-2271-1602

Abstract

Case presentation. A 32-year-old woman consulted for abdominal pain in the epigastrium not associated with meals. She had a history of distal pancreatectomy with spleen preservation due to a tumor in the tail of the pancreas five years earlier. Physical examination showed no abnormalities and imaging studies were performed during his approach. **Treatment.** Computed axial tomography revealed a lesion in the left lateral segment of the liver with characteristics suggestive of metastasis due to his surgical history. Laboratory tests and tumor markers were within normal limits. It was evaluated in a multidisciplinary conference, and a surgical approach was recommended. A left hepatectomy was performed with an uncomplicated postoperative evolution. **Outcome.** Six months postoperatively, there was no evidence of active or residual disease.

Keywords

Pancreas, Neoplasms, Liver, Metastasis, Metachronous Neoplasm.

Resumen

Presentación del caso. Se trata de una mujer de 32 años quien consultó por dolor abdominal en el epigastrio no asociado a las comidas, tenía el antecedente de una pancreatectomía distal con preservación de bazo debido a un tumor en la cola del páncreas, cinco años previos. En el examen físico no presentó ninguna anormalidad y durante su abordaje se realizaron estudios de imagen. **Intervención terapéutica.** La tomografía axial computarizada evidenció una lesión en el segmento lateral izquierdo del hígado con características sugestivas de metástasis debido a su antecedente quirúrgico. Los exámenes de laboratorio y marcadores tumorales se encontraron dentro de límites normales. Se evaluó en conferencia multidisciplinaria y se recomendó un abordaje quirúrgico. Se realizó una hepatectomía izquierda con una evolución posquirúrgica sin complicaciones. **Evolución clínica.** Luego de seis meses posoperatorios, se encontraba sin evidencia de enfermedad activa o residual.

Palabras clave

Páncreas, neoplasia, hígado, metástasis, neoplasia metacrónica.

Introduction

Pseudopapillary solid tumors of the pancreas are considered a rare pathology, representing only 1-2 % of all exocrine tumors of the pancreas.ⁱ Pseudopapillary solid tumors of the pancreas were first reported by Frantz in 1959; thus, they were known as Frantz's tumors at one time.ⁱⁱ Currently, the World Health Organization classifies them as tumors of the digestive

system, of low grade of malignancy, but with the potential to cause metastasis; with a report in the literature of approximately 8334 cases as of 2018.ⁱⁱⁱ The cause of these tumors is still unknown.^{iv}

About 90 % of the cases occur in young women, with an average age of 23.9 years.^v Most solid lesions of the pancreas are considered malignant; however, this type of tumor has a less aggressive behavior and rarely metastasizes.ⁱⁱ

OPEN ACCESS

Metástasis hepática metacrónica de un tumor sólido pseudopapilar de páncreas

Suggested citation:

Alfaro Varela JC, Interiano Tobar MF, Álvarez Salazar GE. Metachronous liver metastasis from a solid pseudopapillary pancreas tumor. *Alerta*. 2024;7(2):133-137. DOI: 10.5377/alerta.v7i2.17065

Editor:

Larisa Chavarría.

Received:

August 30, 2023.

Accepted:

May 6, 2024.

Published:

July 24, 2024.

Author contribution:

JCAVⁱ: study conception, manuscript design, literature search, data analysis, writing, revision and edition. MFITⁱⁱ: manuscript design, data management, data analysis, writing, revision and edition. GEASⁱⁱⁱ: data collection, data management, data analysis, writing, revision and edition.

Conflicts of interest:

The authors declared there was not conflict of interests.



© 2024 by the authors. This is an open access article distributed under the terms and conditions of the Creative Commons Attribution (CC BY) license (<https://creativecommons.org/licenses/by/4.0/>).

Generally, these tumors do not present symptoms and are incidental findings. The presence of metastatic lesions is infrequent, and there is no consensus as to the ideal management in these cases since these solid pseudopapillary tumors of the pancreas do not respond adequately to chemotherapy or radiotherapy, so surgical resection is the ideal curative treatment, even in the presence of metastatic lesions.^{vi} Due to the infrequent nature of the pathology, this case is considered to be of interest, as only isolated cases have been reported.

Case presentation

The patient was a 32-year-old woman who consulted a tertiary-level hospital for abdominal pain located in the epigastrium, not associated with food intake, and did not present jaundice, weight loss, or other symptoms. She had a history of distal pancreatectomy with spleen preservation due to a tumor in the tail of the pancreas five years earlier. The histopathologic biopsy result reported a solid pseudopapillary neoplasm of the pancreas with healthy surgical borders; no nodal status was included. She was referred to a tertiary hospital for evaluation and treatment by oncology. She received chemotherapy and radiotherapy in an unknown amount and three years after discontinuation of follow-up by the specialty.

Vital signs were reported without abnormalities, with a blood pressure of 120/70 mmHg, a heart rate of 72 bpm, and a temperature of 37 °C. A physical examination did not identify masses or signs of peritoneal irritation. Due to the oncologic history, tumor markers (CA19-9 and CEA) were indicated and reported within normal limits, and the rest of the laboratory tests (Table 1).

Abdomino-pelvic tomography described a hypodense lesion in hepatic segment II, with

a well-defined wall and enhancement in the contrasted phase measuring 5.8 × 4.4 × 4.4 cm with a complex cystic component of indeterminate behavior (Figure 1).

A hypodense lesion of 37 Hounsfield Units (HU) in the venous phase and 49 HU in the arterial phase was observed, measuring 5.8 × 4.4 × 4.4 cm with the cystic component.

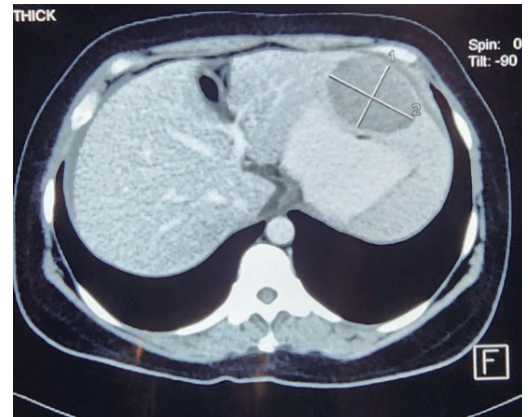


Figure 1. Abdomino-pelvic computed axial tomography

Treatment

The multidisciplinary hepato-pancreato-biliary committee of the tertiary care hospital evaluated the case, took into account the medical history and the characteristics of the images, and therefore concluded with the presumptive preoperative diagnosis of a hepatic metastasis secondary to the previously removed solid pseudopapillary tumor of the pancreas; consequently, they suggested performing a left lateral hepatectomy (bi-segmentectomy II-III) without the need for preoperative biopsy, and without receiving chemotherapy or radiotherapy preoperatively.

Surgical intervention was performed with a midline approach, in which a mass was evidenced in segments II and III of the liver, measuring 10 × 15 cm in diameter; no other metastatic lesions were found (Figure 2). Vascular control was performed using the Pringle maneuver and continued with the release of the suspensory ligaments of the liver (coronal and triangular). The transection site in the liver was marked, and the hepatectomy was performed with a dissector and ultrasonic aspirator. The estimated blood loss was 200 mL with an operative time of 120 minutes. Hemostasis was verified at the parenchymal transection site, titanium clips were used to occlude the segmental bile duct, and hemostatic material was left in the hepatic remnant (Figure 3).

Table 1. Laboratory tests

Hemoglobin	14 gr/dL (VN: 12-16)
Plaquettes	255 000 (VN: 150-400 mil)
Aspartate aminotransferase (AST)	25 UI (VN: 0-45 IU)
Alanine aminotransferase (ALT)	20 UI (VN: 0-50 IU)
Total Bilirubin	0,9 mg/dL (VN: < 1,1 mg/dL)
CA 19-9 antigen	0 (VN: 0-35)
Carcinoembryonic antigen (CEA)	0 (VN: 0-5)

*NV: Normal value.

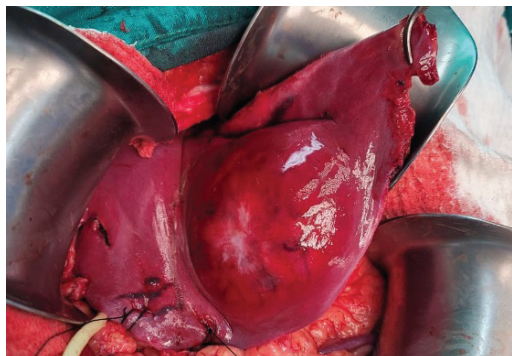


Figure 2. Lesion of the left lateral hepatic lobule, 10 × 15 cm in segments II and III. Release of the triangular and coronary ligaments is observed

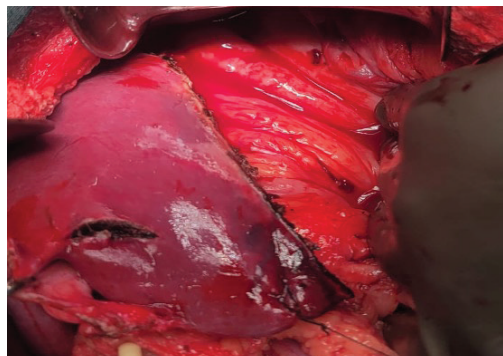


Figure 3. Hepatic remnant with the transection zone and macroscopic edges free of tumor

Outcome

She received analgesia with paracetamol 1 g IV every eight hours in the immediate postoperative period. She also had a satisfactory evolution and was discharged 48 hours after surgery with a follow-up plan in the Oncology Unit. There was no need for transfusion of blood products or special care management.

In the resected specimen, a limited and well-encapsulated large lesion was observed concerning the surface of the liver without involvement of neighboring organs or other metastatic lesions. Examination of the specimen revealed solid tissue with some cystic components of heterogeneous consistency (Figure 4). The pathology report described a metastatic lesion of a pseudopapillary solid tumor of the pancreas, with negative borders and a well-demarcated fibrous capsule. No chemotherapy or radiotherapy was deemed necessary.

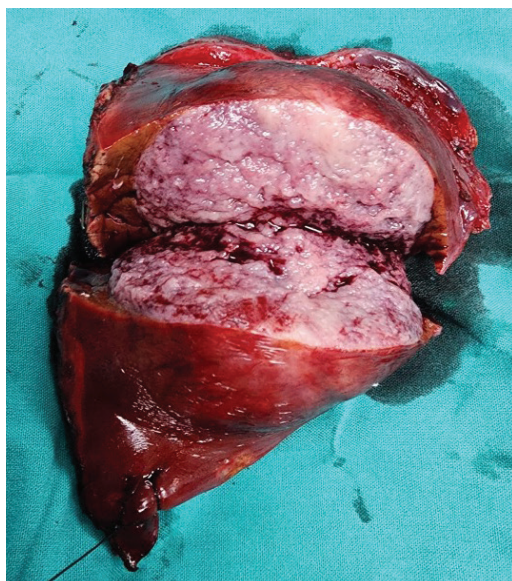


Figure 4. A solid lesion with well-encapsulated cystic components and macroscopically free surgical margins

Clinical diagnosis

The definitive diagnosis, based on the anatomopathological study, was a solid pseudopapillary tumor of the pancreas, as a metastatic lesion of the liver, by the history of the tumor in the pancreas.

Discussion

Pseudopapillary solid tumors of the pancreas are a rare disease that predominates in young women, with a ninefold increase.^v Although in men it is diagnosed at an advanced age.^{vii} Moreover, more aggressive behavior has been reported in men and postmenopausal women, suggesting that the biology of the tumor may be related to estrogen stimulation[!]. The biological behavior is still uncertain.

On the other hand, surgical resection is considered the best therapeutic option in all cases, even in the presence of metastatic lesions or extension to neighboring organs.^{viii,ix} The most frequent site of location is the body and tail of the pancreas, followed by the head,^x and the liver, lymph nodes, omentum, and peritoneum are mentioned as the organs with the highest frequency of metastasis.^{xi}

Abdominal pain (51.6 %) and palpation of an abdominal mass (40.2 %) have been described as the main symptoms, although asymptomatic disease occurs in 38.6 % of cases.^x In approximately 85 % of patients, the disease is limited to the pancreas and metastatic lesions are identified during surgery in only 10 to 15 %.^{xiii} On the other hand, distant metastases are rare events, occurring in 7.7 % of cases.^{xiii} In this case, the site of metastasis was the liver, and was diagnosed six years after the index surgery.

These tumors do not respond to chemotherapy or radiotherapy, which makes surgical treatment their best option.^{vi} Because of this, surgery is consid-

ered to be the standard curative procedure with a better survival rate, greater than 97 % at five years, compared to other tumors such as pancreatic adenocarcinomas.^{xii} Other treatments, such as radiofrequency ablation or chemoembolization (TACE), are not fully proven as curative.^{vi}

Currently, there are no guidelines on the management of these metastatic lesions to the liver.^{xiv} Some authors have recommended enucleation of the tumors to preserve the parenchyma in very selected cases, such as peripheral location and a distance greater than 3 mm from the bile duct or the main pancreatic duct; however, they are not accepted.^{xv} In cases where metastases are not resectable, liver transplantation has been reported as a therapeutic option with acceptable results.^{xvi} Resection of the primary tumor and metastasis is also recommended, providing excellent survival as long as all lesions are removed.^{xvii}

Because the present case was solitary and resectable, a surgical procedure was decided upon to offer the best chance of survival, even with the uncertainty of its biological behavior. A meta-analysis demonstrated a mean disease-free time of approximately 150 months in cases with systemic involvement.^{xviii} Another study showed that patients with local recurrence or peritoneal implants have a long survival, an average time to report metastases of 8.5 years, and generally in patients older than 36 years.^{xix}

The presence of metastases to the liver at the time of diagnosis is common; however, a more aggressive biological behavior compared to metastases in other sites has not been evidenced.^{xi} Some authors have described cases that have been successfully treated by multistage surgery for multiple liver lesions.^{xiv,xx} Five and ten-year disease-free survival is approximately 70 % and 65 % respectively in cases with aggressive behavior.^{xviii} At the molecular level, it has been shown that genetic alterations in BAP1 and KDM6A may be related to the metastatic potential of this type of tumor.^{xxi} Because these lesions have an uncertain behavior, it is suggested that follow-up should be longer than five years.^{xxii}

Ethical aspects

This work complies with the standards established in the Declaration of Helsinki and Belmont, respecting the patient's identity and all ethical aspects. The information is confidential, with the patient's informed consent for the disclosure of the information for scientific purposes.

Funding

No external funds were received for this work.

References

- i. Antoniou EA, Damaskos C, Garpis N, Salakos C, Margonis G-A, Kontzoglou K, *et al*. Solid Pseudopapillary Tumor of the Pancreas: A Single-center Experience and Review of the Literature. In Vivo. 2017;31(4):501-510. Available at: <http://iv.iiarjournals.org/content/31/4/501.abstract>
- ii. Huang H-L, Shih S-C, Chang W-H, Wang T-E, Chen M-J, Chan Y-J. Solid-pseudopapillary tumor of the pancreas: Clinical experience and literature review. World Journal of Gastroenterology. 2005;11(9):1403-1409. DOI: [10.3748/wjg.v11.i9.1403](https://doi.org/10.3748/wjg.v11.i9.1403)
- iii. Jena SS, Ray S, Das SAP, Mehta NN, Yadav A, Nundy S. Rare Pseudopapillary Neoplasm of the Pancreas: A 10-Year Experience. Surgery Research and Practice. 2021;2021:e7377991. DOI: [10.1155/2021/7377991](https://doi.org/10.1155/2021/7377991)
- iv. La Rosa S, Bongiovanni M. Pancreatic Solid Pseudopapillary Neoplasm: Key Pathologic and Genetic Features. Archives of Pathology & Laboratory Medicine. 2020;144(7):829-837. DOI: [10.5858/arpa.2019-0473-RA](https://doi.org/10.5858/arpa.2019-0473-RA)
- v. Mao C, Guvendi M, Domenico DR, Kim K, Thomford NR, Howard JM. Papillary cystic and solid tumors of the pancreas: A pancreatic embryonic tumor? Studies of three cases and cumulative review of the world's literature. Surgery. 1995;118(5):821-828. DOI: [10.1016/S0039-6060\(05\)80271-5](https://doi.org/10.1016/S0039-6060(05)80271-5)
- vi. Tanoue K, Mataka Y, Kurahara H, Idichi T, Kawasaki Y, Yamasaki Y, *et al*. Multidisciplinary treatment of advanced or recurrent solid pseudopapillary neoplasm of the pancreas: three case reports. Surgical Case Reports. 2022;8(1):7. DOI: [10.1186/s40792-022-01358-0](https://doi.org/10.1186/s40792-022-01358-0)
- vii. Kotecha K, Pandya A, Gill AJ, Mittal A, Samra J. Pancreatic solid pseudopapillary neoplasm: a single-institution study. ANZ J Surg. 2021;91(11):2453-2458. DOI: [10.1111/ans.17142](https://doi.org/10.1111/ans.17142)
- viii. Cruz MAA, Moutinho-Ribeiro P, Costa-Moreira P, Macedo G. Solid Pseudopapillary Neoplasm of the Pancreas: Unfolding an Intriguing Condition. GE - Portuguese Journal of Gastroenterology. 2021;29(3):151-162. DOI: [10.1159/000519933](https://doi.org/10.1159/000519933)
- ix. Sibio S, Carlo SD. Current highlights on solid pseudopapillary neoplasm of the pancreas. World Journal of Hepatology. 2022;14(1):300-303. DOI: [10.4254/wjh.v14.i1.300](https://doi.org/10.4254/wjh.v14.i1.300)

- x. Yao J, Song H. A Review of Clinicopathological Characteristics and Treatment of Solid Pseudopapillary Tumor of the Pancreas with 2450 Cases in Chinese Population. *BioMed Research International*. 2020; e2829647. DOI: [10.1155/2020/2829647](https://doi.org/10.1155/2020/2829647)
- xi. Law JK, Ahmed A, Singh VK, Akshintala VS, Olson MT, Raman SP, *et al*. A Systematic Review of Solid-Pseudopapillary Neoplasms: Are These Rare Lesions? *Pancreas*. 2014;43(3):331. DOI: [10.1097/MPA.0000000000000061](https://doi.org/10.1097/MPA.0000000000000061)
- xii. Tang LH, Aydin H, Brennan MF, Klimstra DS. Clinically Aggressive Solid Pseudopapillary Tumors of the Pancreas: A Report of Two Cases With Components of Undifferentiated Carcinoma and a Comparative Clinicopathologic Analysis of 34 Conventional Cases. *The American Journal of Surgical Pathology*. 2005;29(4):512. DOI: [10.1097/01.pas.0000155159.28530.88](https://doi.org/10.1097/01.pas.0000155159.28530.88)
- xiii. Wang X, Chen Y-H, Tan C, Zhang H, Xiong J, Chen H, *et al*. Enucleation of pancreatic solid pseudopapillary neoplasm: Short-term and long-term outcomes from a 7-year large single-center experience. *European Journal of Surgical Oncology*. 2018;44(5):644-650. DOI: [10.1016/j.ejso.2018.01.085](https://doi.org/10.1016/j.ejso.2018.01.085)
- xiv. Wójciak M, Gozdowska J, Pacholczyk M, Lisik W, Kosieradzki M, Cichocki A, *et al*. Liver Transplantation for a Metastatic Pancreatic Solid-Pseudopapillary Tumor (Frantz Tumor): A Case Report. *Ann Transplant*. 2018;23:520-523. DOI: [10.12659/AOT.908764](https://doi.org/10.12659/AOT.908764)
- xv. Hu S, Zhang H, Wang X, Sun Z, Ge Y, Yan G, *et al*. Asymptomatic versus symptomatic solid pseudopapillary tumors of the pancreas: clinical and MDCT manifestations. *Cancer Imaging*. 2019;19(1):13. DOI: [10.1186/s40644-019-0198-4](https://doi.org/10.1186/s40644-019-0198-4)
- xvi. Omiyale AO. Solid pseudopapillary neoplasm of the pancreas. *World Journal of Hepatology*. 2021;13(8):896-903. DOI: [10.4254/wjh.v13.i8.896](https://doi.org/10.4254/wjh.v13.i8.896)
- xvii. Ranaweera K, Nandasena M, de Silva U, Jayarajah U, Delwatta S, de Silva C, *et al*. Solid pseudopapillary neoplasm of the pancreas with multiple liver metastases successfully managed with staged resection. *SAGE Open Medical Case Reports*. 2022;10:2050313X221101995. DOI: [10.1177/2050313X221101995](https://doi.org/10.1177/2050313X221101995)
- xviii. Hao EU, Hwang HK, Yoon D-S, Lee WJ, Kang CM. Aggressiveness of solid pseudopapillary neoplasm of the pancreas: A literature review and meta-analysis. *Medicine*. 2018;97(49):e13147. DOI: [10.1097/MD.00000000000013147](https://doi.org/10.1097/MD.00000000000013147)
- xix. González Cámpora R, Rios Martin JJ, Villar Rodriguez JL, Ota Salaverri C, Hevia Vazquez A, Valladolid JM, *et al*. Papillary cystic neoplasm of the pancreas with liver metastasis coexisting with thyroid papillary carcinoma. *Arch Pathol Lab Med*. 1995;119(3):268-273. Available at: <https://pubmed.ncbi.nlm.nih.gov/7887782/>
- xx. Morito A, Eto K, Matsuishi K, Hamasaki H, Morita K, Ikeshima S, *et al*. A case of repeat hepatectomy for liver metastasis from solid pseudopapillary neoplasm of the pancreas: a case report. *Surg Case Rep*. 2021;7(1):60. DOI: [10.1186/s40792-021-01134-6](https://doi.org/10.1186/s40792-021-01134-6)
- xxi. Amato E, Mafficini A, Hirabayashi K, Lawlor RT, Fassan M, Vicentini C, *et al*. Molecular alterations associated with metastases of solid pseudopapillary neoplasms of the pancreas. *J Pathol*. 2019;247(1):123-134. DOI: [10.1002/path.5180](https://doi.org/10.1002/path.5180)
- xxii. Lee G, Sung Y-N, Kim SJ, Lee JH, Song K-B, Hwang DW, *et al*. Large tumor size, lymphovascular invasion, and synchronous metastasis are associated with the recurrence of solid pseudopapillary neoplasms of the pancreas. *HPB*. 2021;23(2):220-230. DOI: [10.1016/j.hpb.2020.05.015](https://doi.org/10.1016/j.hpb.2020.05.015)