

# Acute Vector-transmitted Chagas in Pediatric Age. A Case Report

DOI: 10.5377/alerta.v7i2.16814

Reina Iris Chávez Fuentes<sup>1\*</sup>, Maury Reinaldo Silva Granados<sup>2</sup>, Norma Patricia Lemus Pineda<sup>3</sup>

1. Ministry of Public Health, National Institute of Health, San Salvador, El Salvador.  
2-3. Ministry of Public Health, Health Surveillance Unit, San Miguel, El Salvador.

\*Correspondence

✉ irischavez.r@gmail.com

1. 0009-0001-8461-9948
2. 0009-0006-3058-1776
3. 0009-0007-1972-4374

## Abstract

**Case presentation.** A seven-year-old female patient, with no previous medical history, originally from a rural area of the department of San Miguel, who presented febrile process plus long-term right bpalpebral edema of six weeks of evolution, without accompanying symptoms. Immunoglobulin M for Chagas was positive, direct microscopy by fresh drop and Strout technique was performed with negative results. In community interventions, the presence of the vector and its positivity were identified, as well as the diagnosis of a chronic case in another family member. **Treatment.** The patient was treated with nifurtimox 150 mg every eight hours for 60 days, subsequent controls were performed to investigate side effects of the treatment, and control tests. **Outcome.** With the treatment, the patient evolved with a slight decrease in appetite, and was managed with gastric protectors. Strout's concentrate and fresh gout were negative and the other laboratory tests were within normal ranges.

## Keywords

Chagas Disease, *Trypanosoma cruzi*, Disease Vectors, Neglected Diseases.

## Resumen

**Presentación del caso.** Se trata una niña de siete años de edad, originaria de una zona rural del departamento de San Miguel, quien consultó por presentar fiebre y edema bpalpebral derecho indoloro, de seis semanas de evolución, sin otros síntomas acompañantes. El estudio para el diagnóstico de enfermedad de Chagas fue realizado en una clínica privada; la Inmunoglobulina M para Chagas tuvo un resultado positivo, luego, se realizó la microscopía directa mediante gota al fresco y técnica de Strout con resultado negativo. En las intervenciones comunitarias se identificó la presencia del vector y la positividad del mismo, así como el diagnóstico de un caso crónico en otro miembro de la familia. **Intervención terapéutica.** Se indicó tratamiento con nifurtimox 150 mg cada ocho horas por 60 días y se realizó el seguimiento clínico de la evolución y control de efectos secundarios del tratamiento y exámenes de laboratorio. **Evolución clínica.** Evolucionó con leve disminución del apetito, se manejó con protectores gástricos. El concentrado de Strout y la gota al fresco resultaron negativos y los demás exámenes de laboratorio se mantenían en los rangos normales.

## Palabras clave

Enfermedad de Chagas, *Trypanosoma cruzi*, vectores de enfermedades, enfermedades desatendidas.

## Introduction

Chagas disease is a neglected tropical disease present in the Americas. The protozoan parasite *Trypanosoma cruzi*, the agent of Chagas disease, is a zoonotic pathogen transmitted by triatomine insects.<sup>i</sup>

Transmission can also occur through transfusion of blood components, organ

transplantation, consumption of food or drink contaminated by the vector or its feces, and transmission from mother to fetus during pregnancy.<sup>ii</sup>

It is perceived as a disease linked to poverty because it was once limited to rural areas of Latin America but has spread through migration to non-endemic areas and countries.<sup>iii</sup>

## OPEN ACCESS

### Un caso de Chagas agudo en edad pediátrica

#### Suggested citation:

Chávez Fuentes RI, Silva Granados MR, Lemus Pineda NP. Acute Vector-transmitted Chagas in Pediatric Age. A Case Report. Alerta. 2024;7(2):127-132. DOI: 10.5377/alerta.v7i2.16814

#### Editor:

Larisa Chavarría.

#### Received:

October 3, 2023.

#### Accepted:

May 11, 2024.

#### Published:

July 24, 2024.

#### Author contribution:

RICF<sup>1</sup>, MRSG<sup>2</sup>: study conception, writing, revising, and editing. RICF<sup>1</sup>: manuscript design, literature search, data management or software. RICF<sup>1</sup>, MRSG<sup>2</sup>, NPLP<sup>3</sup>: data collection.

#### Conflict of interests:

The authors declared there was not conflict of interests.



© 2024 by the author. This is an open access article distributed under the terms and conditions of the Creative Commons Attribution (CC BY) license (<https://creativecommons.org/licenses/by/4.0/>).

Chagas disease is endemic in 21 countries in the Americas and affects an estimate of six million people. In the region, there are 30 000 new cases each year, 12 000 deaths on average, and approximately 9000 newborns infected during gestation.<sup>iv</sup> El Salvador has long been endemic for Chagas disease; the first case was identified in 1913.<sup>v</sup>

Prevalence in the country is estimated to be between 1.3 % and 3.7 %. Acute cases are rare because most cases are asymptomatic, and only 1-2 % of infected persons experience symptoms.<sup>vi,vii</sup>

Transmission is no longer limited to the Americas, as cases are reported in multiple regions worldwide.<sup>viii</sup> Triatomine insects act as vectors and acquire the parasite when they feed on the blood of an infected mammal. Infected triatomines transmit the parasite in their feces when they defecate during or immediately after feeding.<sup>ix</sup> Vector-borne transmission was the first mechanism of infection described in the history of Chagas disease.

In a small number of cases, entry signs, such as an indurated skin lesion (chagoma) or unilateral bi-palpebral edema (Romaña's sign), can be detected. Most cases are accompanied by mild symptomatology (95-99 %) and go unnoticed. However, persistent fever, fatigue, lymphadenopathy, hepatomegaly, splenomegaly, rash, and edema may occur.<sup>x</sup>

The treatment of *Trypanosoma cruzi* infection consists of drugs authorized for more than 50 years: nifurtimox (launched by Bayer in 1965) and benznidazole (launched by Roche in 1971); their efficacy is conditioned by the stage of infection and the age of the patients therefore, timely diagnosis and knowledge of the disease become relevant in public health.<sup>xi</sup>

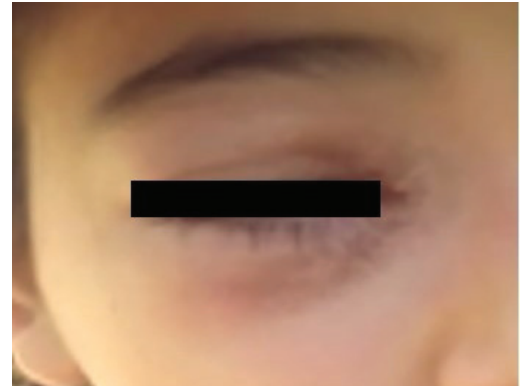The acute phase may be asymptomatic or present with nonspecific general symptoms or complications such as myocarditis or meningoencephalitis, and the diagnosis in this phase is a challenge for physicians.<sup>xii</sup>

## Case presentation

The patient is a seven-year-old girl with a three-day history of unquantified fever and right bi-palpebral edema, painless, of six weeks of evolution, and no other symptoms (Figure 1), and no history of previous diseases. She was diagnosed with an ocular abscess and treated with doxycycline 50 mg orally every 12 hours and ibuprofen 100 mg orally every 12 hours for 10 days.

The patient did not improve after completing the treatment; she consulted a private clinic, where she was examined by an ophthalmologist who suspected Chagas

disease and immediately ordered the immunoglobulin M (IgM) test for Chagas disease at a private clinical laboratory. The test result was positive. Consequently, she was referred to the nearest first-level healthcare facility and then directed to the second-level hospital.



**Figure 1.** Right bi-palpebral edema, with one month of evolution

The patient attended the hospital after five weeks due to difficulties in the access to public transportation in the area where the home is located to travel to the healthcare facility.

The physical examination described bi-palpebral edema of the right eye, with no other findings, and direct microscopy studies (fresh drop) for *T. cruzi*, which consists of direct microscopic observation in search of mobile trypomastigotes in the drop of blood,<sup>xiii</sup> were negative, as were the Strout concentrate and the other laboratory tests (Table 1).

In addition, in a follow-up after one week, samples were taken for testing the family group (mother, father, paternal grandmother, and two adolescent sisters), which consisted of taking Strout's concentrate, blood count, and general chemistry.

Three weeks later, laboratory tests were completed (Strout's concentrate, complete blood count, general chemistry, and IgM for Chagas disease), of which the IgM for Chagas disease was positive, and the patient was diagnosed as a confirmed case of Chagas disease and classified as a case of Chagas disease that does not affect the heart. Finally, it was registered in the epidemiological surveillance system of El Salvador as a case of Chagas disease in the acute phase.

## Treatment

The second-level vector control team conducted a community visit where they identified the house in a rural area of the department of San Miguel. The house is located in an area of difficult vehicular

access, through a dirt road, in an area that does not have public transportation service (Figure 2). The house is made of clay and wood masonry, with a tin roof, distributed in a single space, divided into sections by plastic and with a dirt floor, on a large plot of land of approximately 7000 m<sup>2</sup> with a lot of vegetation and crops, with multiple piles of firewood stacked in the

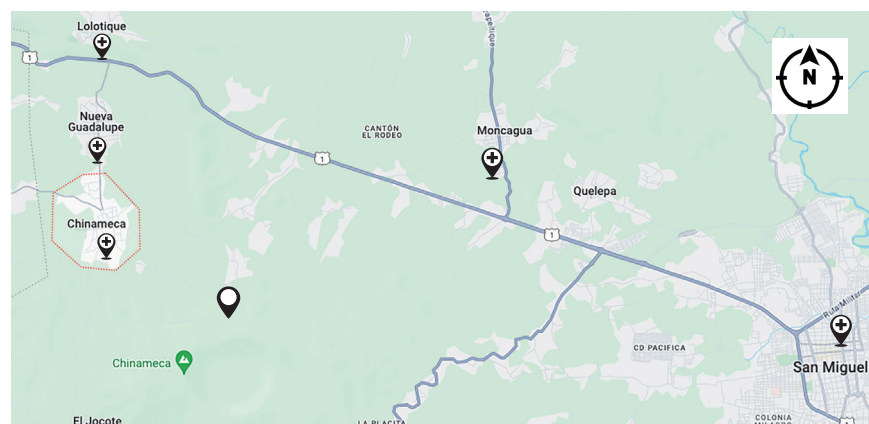
peridomicile and with dogs and chickens as domestic animals (Figure 3).

During entomology control, nine bedbugs were collected with *Triatoma dimidiata* characteristics; three were positive for *Trypanosoma cruzi*. In addition, the test of the paternal grandmother resulted in a case of chronic Chagas disease; she had lived in the place for 20 years.

**Table 1.** Laboratory test results



Test performed	Medical control 1	Medical control 2
Hemoglobin	12.0 g/dL	12.3 g/dL
Hematocrit	34.5 %	36.2 %
Leukocytes	10.0 x10 <sup>3</sup>	8.25 x10 <sup>3</sup>
Neutrophils	51.7 %	53.5 %
Lymphocytes	32.4 %	40.5 %
Platelets	248x10 <sup>3</sup>	370x10 <sup>3</sup>
Protombin time	14.1 sec	-
Thromboplastin time	24.2 sec	-
Blood type	ORh +	-
Direct Bilirubin	0.025 mg/dL	0.04 mg/dL
Indirect Bilirubin	0.17 mg/dL	0.18 mg/dL
Total Bilirubin	0.38 mg/dL	0.42 mg/dL
Creatinine	0.6 mg/dL	0.6 mg/dL
Urea Nitrogen	7.2 mg/dL	7.6 mg/dL
Uric acid	2.3mg/dL	2.4mg/dL
Sodium	142 mmol/L	139.8 mmol/L
Potassium	4.1 mmol/L	4.0 mmol/L
Chlorine	99.7 mmol/L	99.1 mmol/L
Aspartate aminotransferase	32.6 U/L	28.3 U/L
Alanine aminotransferase	17.5 U/L	17.5 U/L
Triglycerides	-	89.8 mg/dL
Fresh drop for <i>T. cruzi</i>	There is no evidence of <i>T. cruzi</i> in the preparation	There is no evidence of <i>T. cruzi</i> in the preparation
Strout concentrate	There is no evidence of <i>T. cruzi</i> in the preparation	There is no evidence of <i>T. cruzi</i> in the preparation
Qualitative IgM Chagas	Positive	2,27 Reactive

Source: clinical record



Source: Google maps.

**Figure 2.** Geographical location of the house

-  Healthcare facility
-  Location of the house

**16,1 km (29 min):** distance from the house to the first level of healthcare service.

The treatment for the patient was nifurtimox, at a dose of 18 mg/kg/dose, 150 mg every eight hours for 60 days, and medical follow-up and laboratory tests every two weeks.

### Outcome

A clinical improvement was evidenced. In the second follow-up, after 27 days of treatment, the patient presented mild hyporexia as a secondary symptom to the drug and was prescribed omeprazole 20 mg daily. In addition, the results of Strout's concentrate and fresh gout were negative and the complementary tests (hemogram, liver, and renal function tests) were within normal ranges (Table 1).

### Clinical diagnostic

The diagnosis of Chagas disease was confirmed by an IgM test, with two positive results through different times of the disease (Figure 4).

### Discussion

The case describes a seven-year old girl with manifestations of the disease in its acute phase. After the study of the clinical, epidemiological, and biological factors, the disease and the presence and positivity of the vector were proven. In the initial clinical picture, she presented Romaña sign and febrile process and had a positive IgM result for Chagas disease.



Figure 3. Photos of the house

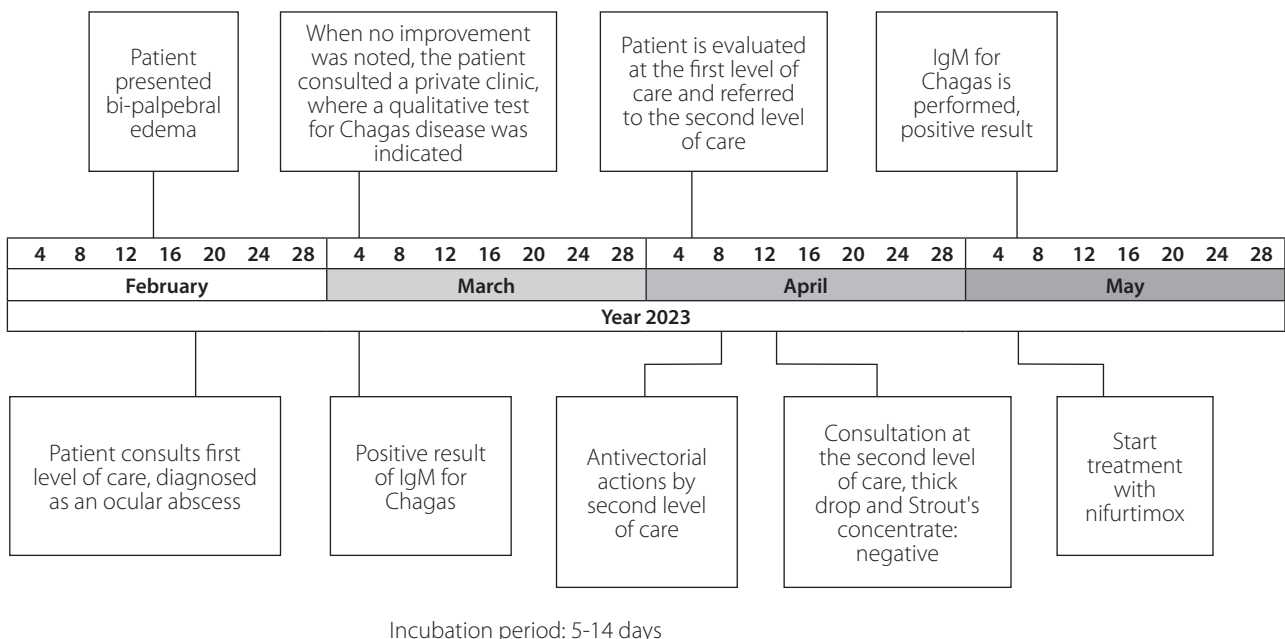


Figure 4. Timeline

Entomological surveillance consisted of analysis of the vectors found in the dwelling with a positivity index of 33.3 %; a high-risk infestation index is considered when it is higher than 5.0 %, according to entomological parameters.<sup>xiii</sup>

The diagnosis of Chagas disease depends on the stage of the disease the patient is found.<sup>xiv</sup> Most patients are asymptomatic during the acute phase; about 30 % progress to detectable organ damage involving mainly the cardiovascular and digestive systems. The acute phase lasts four to eight weeks before it resolves spontaneously, leaving most patients chronically infected if untreated. The parasite in the acute phase can only be detected directly by microscopic observation of a fresh drop, which has motile parasites among red blood cells,<sup>xv</sup> or through Strout's method, which allows the parasites to settle to the bottom of the tube where the sample is processed.<sup>xvi</sup> In El Salvador, according to the guidelines for the prevention, surveillance, and control of vector-borne diseases and zoonoses, "in the acute phase of Chagas disease, the diagnosis must be confirmed using direct methods without prior concentration (fresh drop), or direct concentration methods (microhematocrit and Strout technique)."<sup>xviii</sup>

As for the diagnosis of the case, in the acute phase, there may be a decrease in the parasite load one month after the primary infection. The sensitivity of diagnostic methods is limited in patients with low parasitemia, who present negative successive examinations. If the parasite is difficult to find during the acute phase, it is useful to apply the diagnostic search through specific IgM for *T. cruzi*.<sup>xvii</sup>

The drugs used have some disadvantages, including their efficacy only in the acute or early stages of infection, making early diagnosis of the disease of vital importance.<sup>xviii</sup>

On the other hand, the timeline evaluation shows that there were limitations in the diagnosis due to the lack of inquiry into the epidemiological links of the disease, as a result of the delay in follow-up and treatment due to the difficult access to health-care services by the patient and the family group, which constitutes a geographical and socio-economic barrier in the search for medical care and the initiation of timely medical treatment.<sup>xix</sup>

It is a known fact that the disease is transmitted by the vector residing in the mud walls of rural houses in developing countries; in this sense, the investigation of the epidemiological link is part of the clinical evaluation in those cases that present

symptoms suggestive of the disease for proper diagnosis and treatment. In addition, in this sense, serious health complications are prevented in the future.<sup>xx,xxi</sup>

## Ethical aspects

Assent was obtained from the minor patient and consent from the responsible mother, as her authorization for the publication of the clinical case and images, in accordance to the Helsinki Declaration and international ethical guidelines for health-related research involving human beings.

## Acknowledgments

To Rómulo Vides, medical epidemiologist at Nueva Guadalupe Hospital, San Miguel, and Erick López Echeverría, medical doctor at Healthcare Unit, Chinameca, for their support in the clinical and epidemiological investigation of the patient.

## Funding

There were not external funds for this study.

## References

- i. Busselman RE, Hamer SA. Chagas Disease Ecology in the United States: Recent Advances in Understanding *Trypanosoma cruzi* Transmission Among Triatomines, Wildlife, and Domestic Animals and a Quantitative Synthesis of Vector-Host Interactions. *Annu Rev Anim Biosci*. 2022;10:325-348. DOI: [10.1146/annurev-animal-013120-043949](https://doi.org/10.1146/annurev-animal-013120-043949)
- ii. Bern C, Messenger LA, Whitman JD, Maguire JH. Chagas Disease in the United States: a Public Health Approach. *Clinical Microbiology Reviews*. 2019;33(1):10.1128/cmr.00023-19. DOI: [10.1128/cmr.00023-19](https://doi.org/10.1128/cmr.00023-19)
- iii. Suárez C, Nolder D, García-Mingo A, Moore DA, Chiodini PL. Diagnosis and Clinical Management of Chagas Disease: An Increasing Challenge in Non-Endemic Areas. *RRTM*. 2022;13:25-40. DOI: [10.2147/RRTM.S278135](https://doi.org/10.2147/RRTM.S278135)
- iv. Organización Panamericana de la Salud. Enfermedad de Chagas. OPS-OMS. 2024. Consulted date: 31 de mayo de 2024. Available at: <https://www.paho.org/es/temas/enfermedad-chagas>
- v. Nolan MS, Murray KO, Mejia R, Hotez PJ, Villar Mondragon MJ, Rodriguez S, et al. Elevated Pediatric Chagas Disease Burden Complicated by Concomitant Intestinal Parasites and Malnutrition in El Salvador. *Tropical Medicine and Infectious*

- Disease. 2021;6(2):72. DOI: [10.3390/tropicalmed6020072](https://doi.org/10.3390/tropicalmed6020072)
- vi. Beltrami M, Grande R, Giacomelli A, Sabaini F, Biondo L, Longo M, *et al.* Chagas disease prevalence among migrants from El Salvador in Milan: a cross-sectional study of an often-overlooked population. *Infectious Diseases*. 2023;55(8):559-566. DOI: [10.1080/23744235.2023.2222817](https://doi.org/10.1080/23744235.2023.2222817)
  - vii. Sasagawa E, de Aguilar AVG, de Ramírez MAH, Chévez JER, Nakagawa J, Cedillos RA, *et al.* Acute Chagas disease in El Salvador 2000-2012 - Need for surveillance and control. *Mem Inst Oswaldo Cruz*. 2014;109(2):256-258. DOI: [10.1590/0074-0276140416](https://doi.org/10.1590/0074-0276140416)
  - viii. Peña Callejas G, James González J, Jiménez Cortés G, Fuentes Vicente JA, Salazar Schettino PM, Bucio Torres MI, *et al.* Enfermedad de Chagas: biología y transmisión de *Trypanosoma cruzi*. *TIP Revista Especializada en Ciencias Químico-Biológicas*. 2022;25:1-19. DOI: [10.22201/fesz.23958723e.2022.449](https://doi.org/10.22201/fesz.23958723e.2022.449)
  - ix. Agudelo Higuera NI, Bronze MS, Smith JW, Montgomery SP. Chagas disease in Oklahoma. *Am J Med Sci*. 2022;364(5):521-528. DOI: [10.1016/j.amjms.2022.03.018](https://doi.org/10.1016/j.amjms.2022.03.018)
  - x. Schijman AG, Alonso-Padilla J, Longhi SA, Picado A. Parasitological, serological and molecular diagnosis of acute and chronic Chagas disease: from field to laboratory. *Mem. Inst. Oswaldo Cruz*. 2022;117:e200444. DOI: [10.1590/0074-02760200444](https://doi.org/10.1590/0074-02760200444)
  - xi. Pérez Molina JA, Crespillo Andújar C, Bosch-Nicolau P, Molina I. Trypanocidal treatment of Chagas disease. *Enfermedades infecciosas y microbiología clínica (English ed.)*. 2021;39(9):458-470. DOI: [10.1016/j.eimce.2020.04.012](https://doi.org/10.1016/j.eimce.2020.04.012)
  - xii. Montoya DD, Ríos JPO. Enfermedad de Chagas y sus manifestaciones neurológicas. *Acta Neurológica Colombiana*. 2021;37(1 Supl 1):154-162. DOI: [10.22379/24224022348](https://doi.org/10.22379/24224022348)
  - xiii. Ministerio de Salud. Lineamientos técnicos para la prevención, vigilancia y control de enfermedades transmitidas por vectores y zoonosis. Ministerio de Salud. 2020. 228 p. Available at: <https://asp.salud.gob.sv/regulacion/pdf/lineamientos/lineamientostecnicosparalaprevencionvigilanciaycontroldenfermedadestransmitidasporvectoresyzoonosis-Acuerdo1006.pdf>
  - xiv. Echavarría NG, Echeverría LE, Stewart M, Gallego C, Saldarriaga C. Chagas Disease: Chronic Chagas Cardiomyopathy. *Current Problems in Cardiology*. 2021;46(3):100507. DOI: [10.1016/j.cpcardiol.2019.100507](https://doi.org/10.1016/j.cpcardiol.2019.100507)
  - xv. Teixeira ARL, Nitz N, Guimaro MC, Gomes C. Chagas disease. *Postgrad Med J*. 2006;82(974):788-798. DOI: [10.1136/pgmj.2006.047357](https://doi.org/10.1136/pgmj.2006.047357)
  - xvi. Malik LH, Singh GD, Amsterdam EA. The Epidemiology, Clinical Manifestations, and Management of Chagas Heart Disease. *Clin Cardiol*. 2015;38(9):565-569. DOI: [10.1002/clc.22421](https://doi.org/10.1002/clc.22421)
  - xvii. Castro-Sesquen YE, Tinajeros F, Bern C, Galdos-Cardenas G, Malaga ES, Valencia Ayala E, *et al.* The Immunoglobulin M-Shed Acute Phase Antigen (SAPA)-test for the Early Diagnosis of Congenital Chagas Disease in the Time of the Elimination Goal of Mother-to-Child Transmission. *Clinical Infectious Diseases*. 2021;73(2):e477-e484. DOI: [10.1093/cid/ciaa986](https://doi.org/10.1093/cid/ciaa986)
  - xviii. García Huertas P, Cardona Castro N. Advances in the treatment of Chagas disease: Promising new drugs, plants and targets. *Biomedicine & Pharmacotherapy*. 2021;142:112020. DOI: [10.1016/j.biopha.2021.112020](https://doi.org/10.1016/j.biopha.2021.112020)
  - xix. Jimeno I, Mendoza N, Zapana F, Torre L de la, Torrico F, Lozano D, *et al.* Social determinants in the access to health care for Chagas disease: A qualitative research on family life in the «Valle Alto» of Cochabamba, Bolivia. *PLoS One*. 2021;16(8):e0255226. DOI: [10.1371/journal.pone.0255226](https://doi.org/10.1371/journal.pone.0255226)
  - xx. Santos É, Menezes Falcão L. Chagas cardiomyopathy and heart failure: From epidemiology to treatment. *Rev Port Cardiol (Engl Ed)*. 2020;39(5):279-289. DOI: [10.1016/j.repc.2019.12.006](https://doi.org/10.1016/j.repc.2019.12.006)
  - xxi. Touriz Bonifaz MA, Santos Paladines PR, Falconi San Lucas S., Tobar Moran MR. Caracterización epidemiológica de la enfermedad de Chagas, en la provincia de Guayas del Ecuador. *RECIMUNDO*. 2021;5(3):149-157. DOI: [10.26820/recimundo/5](https://doi.org/10.26820/recimundo/5)