

Case report

Mesenteric Heterotopic Ossification as a Cause of Intestinal Obstruction in a Patient with a Septic Abdomen

DOI: 10.5377/alerta.v7i1.16210

Sergio Alejandro Valladares Arriaga¹, Rubia Carolina Martínez Monges², Celestina Andrea Larín Jurado³

1-3. Medical Surgical Hospital, Salvadoran Institute of Social Security, San Salvador, El Salvador.

*Correspondence

✉ sergiovalladares094@gmail.com

1.  0009-0004-5754-9683

2.  0009-0003-7232-1866

3.  0009-0002-4813-2339

Abstract

Case presentation. A 49-year-old male, with a history of blunt abdominal trauma with a blunt object without hemodynamic alterations. The focused trauma ultrasound was positive for free fluid in the abdominal cavity in three windows. **Treatment.** The patient underwent multiple exploratory laparotomies with peritoneal lavage after presenting a septic abdomen (Björk 4), who after 38 days of intrahospital stay presented an enteroatmospheric fistula that caused a large nutritional deficit. In a surgical intervention, the enteroatmospheric fistula was closed, with the finding of trabecular bone tissue in the abdominal cavity, corresponding to intra-abdominal heterotopic ossification of recent formation. **Outcome.** After the small intestine anastomosis, he presented signs of intestinal obstruction, because of this, a new exploratory laparotomy was performed, in which bone tissue was found adhered to the mesentery of the small intestine that generated a complete obstruction. The bone material was removed and the intestinal flow was reestablished, freeing the obstruction in the small intestine.

Keywords

Ossification, Heterotopic, Mesentery, Intestinal Obstruction, Sepsis.

Resumen

Presentación del caso. Se trata de un masculino de 49 años, con historia de un trauma abdominal cerrado con un objeto contuso sin alteraciones hemodinámicas. La ecografía focalizada de traumatismos resultó positiva a líquido libre en la cavidad abdominal en tres ventanas. **Intervención terapéutica.** Fue sometido a múltiples laparotomías exploratorias con lavados de cavidad abdominal posterior a presentar un cuadro de abdomen séptico Björk 4, quien después de 38 días de estancia intrahospitalaria presentó una fistula enteroatmosférica que causaba un déficit nutricional. En una intervención quirúrgica se realizó el cierre de la fistula enteroatmosférica, con el hallazgo de tejido óseo trabecular en cavidad abdominal, correspondiente a osificación heterotópica intraabdominal de formación reciente. **Evolución clínica.** Luego de la anastomosis del intestino delgado presentó signos de obstrucción intestinal, a causa de esto, se realizó una nueva laparotomía exploratoria, en la que se encontró tejido óseo adherido al mesenterio del intestino delgado que generó una obstrucción completa, se extirpó el material óseo y se logra restablecer el flujo intestinal liberando la obstrucción en el intestino delgado.

Palabras clave

Osificación Heterotópica, Mesenterio, Obstrucción Intestinal, Sepsis.

Introduction

Heterotopic ossification is a benign process consisting of the formation of bone tissue in tissue other than the skeletal system. It is classified as an infrequent and incidental finding in most cases, that occurs most

frequently as a complication of orthopedic surgery and may be observed during the healing process of midline abdominal incisions. Bone formations have been evidenced in the greater omentum, abdominal wall and rarely in the mesentery.¹

OPEN ACCESS

Osificación heterotópica mesentérica como causa de obstrucción intestinal en un paciente con abdomen séptico

Suggested citation:

Valladares Arriaga SA, Martínez Monges RC, Larín Jurado CA. Mesenteric Heterotopic Ossification as a Cause of Intestinal Obstruction in a Patient with a Septic Abdomen. *Alerta*. 2024;7(1):5-11. DOI: 10.5377/alerta.v7i1.16210

Received:

May 18, 2023.

Accepted:

September 7, 2023

Published:

January 25, 2024.

Authors contribution:

VASA¹: literature search. VASA¹, MMRC²: study conception. VASA¹, MMRC², LJCA³: manuscript design, data collection, writing, revising and editing.

Conflicts of interest:

No conflicts of interest.

Although the mechanism of tissue formation is unclear, some authors describe it as a reactive process with an exuberant response to a traumatic or surgical stimulus. Although studies have attributed this mechanism to infectious and tumor processes, it has also been associated with genetic alterations.ⁱⁱ Other authors suggest that osteoblasts are released into the surrounding tissues when a surgical wound injures the xiphoid appendix.ⁱⁱⁱ The presence of foreign bodies, such as non-absorbable threads, mesh, gauze, abscesses, necrotic tissue, or iodopovidone, can serve as a nidus for heterotopic ossification.^{iv}

Case presentation

A 49-year-old man with no known medical history, who consulted with a history of closed abdominal trauma with a blunt object; he was hit in the hypogastrium with a metal bar. After the event, he was taken to the emergency unit of the regional hospital of San Miguel. He presented diffuse abdominal pain, without alteration in neurological status, alert, oriented, grunting, hemodynamically stable, with blood pressure of 130/95 mmHg, heart rate of 95 beats per minute and weighing of 85 kg. On physical evaluation, he presented moderate abdominal pain.

Focused assessment with sonography in trauma was positive for free fluid in the abdominal cavity in three windows.

Laboratory tests reported leukocytosis with neutrophilia and mild anemia; he underwent an emergency exploratory laparotomy. In this procedure, 2500 mL of blood were found in the abdominal cavity, a small bowel lesion with vascular compromise at the mesentery level, as well as an intestinal segment of 80 cm with ischemic changes. These changes started at 2.90 meters from the angle of Treitz, ending about 10 cm from the ileocecal valve, and a resection and confection of the terminal ileostomy was performed. The abdominal cavity was managed as an open abdomen, utilizing a Bogotá bag, with plans for a second abdominal exploration, subsequently.

After 48 hours, the patient remained stable with a blood pressure of 125/80 mmHg and a heart rate of 88 L/min. A new surgical procedure was undertaken to evaluate the cavity; the abdomen was found to be clean and free of any intestinal leaks. There was no evidence of any free liquid, and the closure was performed by layers using caliber 1 braided multifilament sutures to close the aponeurosis and nylon 1 as retention sutures. Additionally, a Penrose drain was placed. On the tenth day of the hospi-

talization, a culture of the abdominal cavity revealed the presence of *Escherichia coli*. The infection was promptly treated with ceftriaxone 1 g every 12 hours and metronidazole 500 mg every eight hours administered intravenously. After 13 days of hospital stay, he presented deterioration of hemodynamic status with blood pressure of 100/60 mmHg and increased heart rate up to 120 beats per minute. Also, there was evidence of leakage of intestinal material through the surgical wound, and leukocytosis with neutrophilia was reported (Table 1). Consequently, an exploratory laparotomy was performed, which confirmed a septic abdomen with leakage of intestinal material through a perforation in the small intestine of approximately 2 cm, which failed to be categorized at the space from the angle of Treitz due to the presence of a frozen abdomen; the macroscopic characteristics of the intestinal fluid generated the suspicion of localization in the ileum (Figure 1a).

After 21 days of hospitalization, the culture of the abdominal cavity was reported positive for *Pseudomonas aeruginosa*, and antimicrobial therapy was initiated with imipenem cilastatin at a dose of 500 mg intravenous every six hours for 21 days.

Treatment

The patient underwent nine exploratory laparotomies over a period of 38 days, in which cavity washouts were performed with 0.9 % saline solution with an average of four to six liters in each intervention to control the leakage of intestinal material and reduce abdominal contamination. Multiple maneuvers were attempted, such as splinting of the fistula with Foley type catheter (Figure 1b), techniques such as Rivera's condom suture^v (Figure 1c), and placement of a negative pressure system to avoid contamination of the abdominal cavity. In addition, he was given nutritional support with the use of total parenteral nutrition and transferred to the intensive care unit. The use of noradrenaline at a dose of 20 µg/h was necessary, with a gradual reduction of the dose as the septic focus was controlled.

After the control of the enteroatmospheric fistula (Figure 2), it was determined that the patient had a septic abdomen Björk 4,^{vi} with a proximal lesion in the small intestine that generated an approximate output of 2 to 3 L per day; consequently, he presented a nutritional deterioration, with a weight loss of 25 kg, in addition to frequent episodes of dehydration with periods of hypovolemic shock that reverted with the administration of 0.9 % saline solution. For

Table 1. Sequence of laboratory tests

Laboratory test	Days									
	1	3	14	20	43	55	69	74	77	
Leukocytes /mm ³	23 100	14 900	25 000	9480	12 800	13 100	12 260	15 000	8830	
Neutrophils %	86 %	87 %	87 %	74 %	65 %	64 %	85 %	82 %	65 %	
Hemoglobin g/dL	9.7	11	11.7	11.1	11.9	13.4	11.3	8.7	11.2	
Platelets / μ L	184 000	139 000	680 000	423 000	202 000	178 000	252 000	274 000	326 000	
Albumin g/dL	-	2.1	3.2	2.1	3.1	3.3	3.2	2.8	2.2	
Sodium meq/L	137	138	127	137	134	135	135	139	142	
Potassium meq/L	5.1	3.5	4.8	4.1	3.6	4	4	3.5	3.8	
Magnesium mg/dL	1.5	1.8	1.8	1.2	2	2	1.4	2	2	
Calcium mg/dL	7.2	6.7	9	7.8	8.8	9.4	8.2	7.7	7.9	
Chlorine meq/L	103	-	89.7	106	95.5	98.4	100	106	105	
Creatinine mg/dL	1.36	1.22	1.1	1.03	0.99	1.06	0.97	0.89	0.87	
Glucose mg/dL	145	120	113	125	103	88.7	157	122	107	
Urea nitrogen mg/dL	18.5	18.8	25.1	24.2	34.9	35.9	13.8	25.4	11.5	

Fuente: Data obtained from the clinical record.

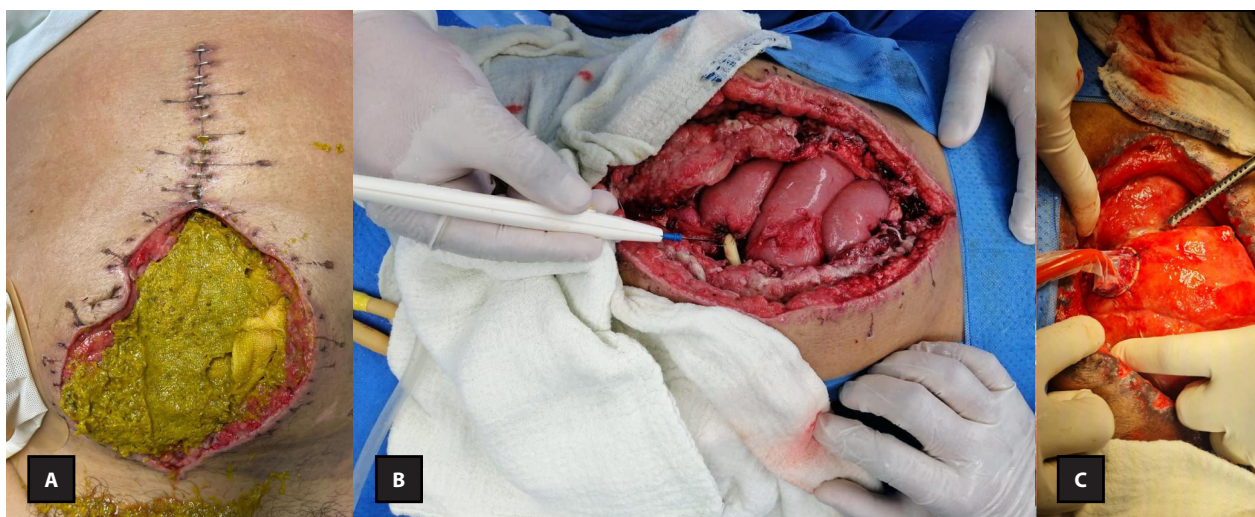

Figure 1. A. Leakage of intestinal material. It is evident when removing the retention stitches, opening of the abdominal cavity with leakage of intestinal material and dehiscence of the aponeurosis. B. Fistula splinting with Foley catheter. C. Rivera´s condom technique

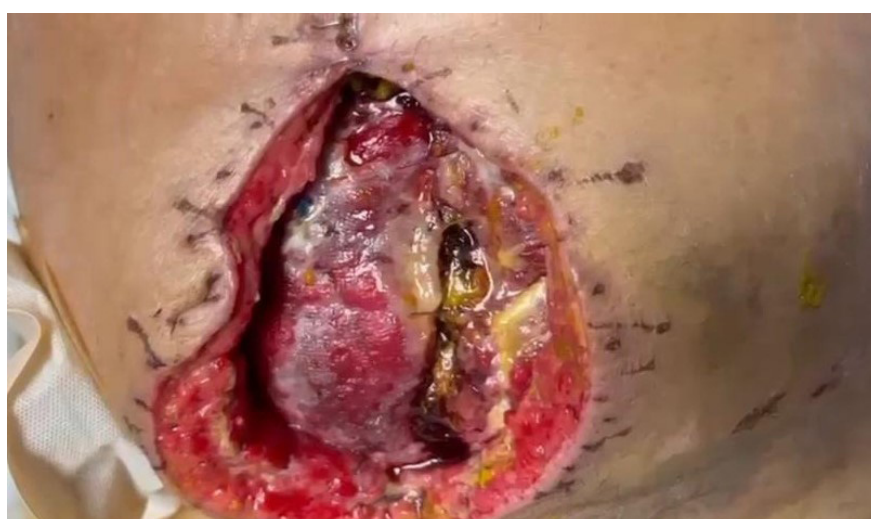

Figure 2. Frozen abdomen, Björk 4

this reason, it was decided to use octreotide at a dose of 0.1 mg subcutaneous every eight hours and loperamide 2 mg orally every eight hours.

Due to the complexity of the case, it was decided to transfer the patient to a specialized center (Medical Surgical Hospital) on the 65th day of in-hospital stay, where he was evaluated by the complex abdominal team and by the nutrition specialty of that hospital. It was decided to perform the tenth exploratory laparotomy with intestinal resection of the fistula segment (Figure 3a) and a manual small bowel anastomosis was performed. The distance from the Treitz angle was not determined because the abdomen was still partially frozen. During this intervention, while the release of the firm adhesions was being performed, a fragment of tissue was found that resembled a bone structure with trabecular appearance located between the intestinal loops and adhered to the mesentery of the terminal ileum that, when extracted, showed scarce bleeding and texture similar to cancellous bone (Figure 3b), and surgical intervention was completed by closing the abdominal wall in layers, including skin.

Forty-eight hours after the surgery, he presented intestinal obstruction, characterized by marked abdominal distention and the absence of output by terminal ileostomy. As a result, an emergency surgery was conducted. During the procedure, multiple firm adhesions were identified between small bowel loops and multiple transition zones between intestinal dilatation and segments with collapsed intestinal lumen. Additionally, a structure resembling bone tissue in the mesentery that conditioned the intestinal obstruction was found.

This generated some areas of complete stenosis without passage of intestinal material through the small intestine, the integrity of the anastomosis performed in previous surgery was confirmed. In light of the findings, the adhesions were dislodged, the segmental regions of heterotopic ossification of the small bowel were extracted, and consequently, the intestinal passage was reestablished (Figure 3c).

On the 72nd day of in-hospital stay, forty-eight hours after surgery, a new surgical intervention was performed in which the abdominal cavity was evaluated, followed by definitive closure of the abdominal wall; the abdomen was found to be clean, without intestinal adhesions, without edema of the intestinal loops, with the anastomosis intact, the aponeurosis retracted and a functional ileostomy, for this reason, definitive closure of the abdominal cavity was performed (Figure 3d).

Outcome

The removal of bone tissue from a portion adjacent to the mesentery of the terminal ileum managed to reverse the obstruction, observing intestinal material outflow through the ileostomy in the transoperative period.

Ileostomy output measurements, which at the beginning was 1300 mL in 24 hours, decreased to output between 800 and 1100 mL in 24 hours after the last intervention, parenteral nutrition was suspended with adequate tolerance to the oral route.

After 75 days of intrahospital stay, the culture of the abdominal cavity was reported positive for *Morganella morganii* spp; for this reason, treatment was started

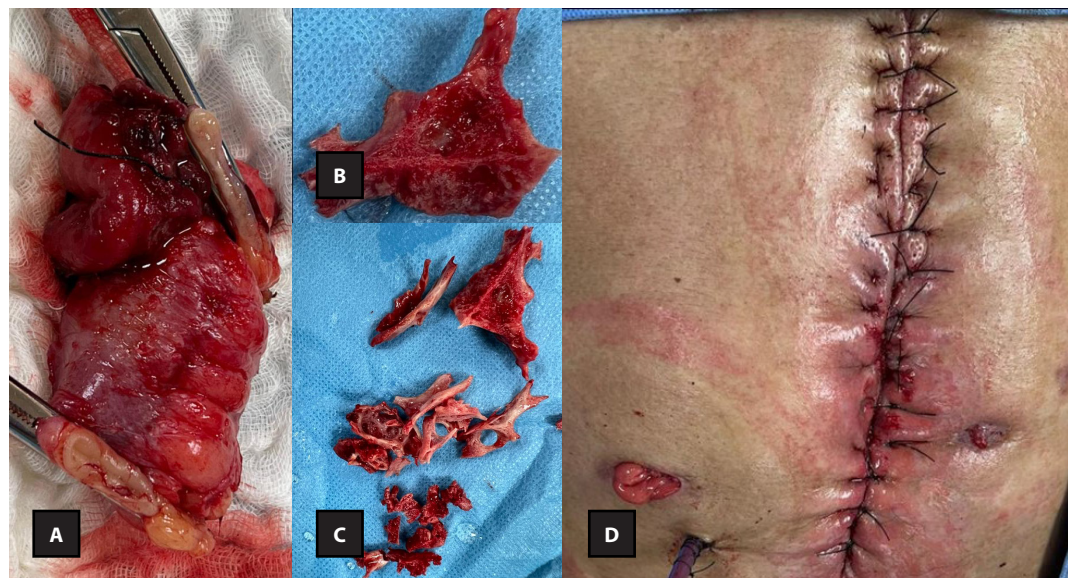

Figure 3. A. Small intestine segment. B and C. Bone fragments. D. Abdominal cavity closure

with ciprofloxacin 0.4 g intravenous every 12 hours for 14 days.

Complementary imaging and laboratory studies were performed that could be associated with heterotopic ossification. Abdomino-pelvic computed tomography on the 78th day of in-hospital stay identified bony formations adhered to the small bowel mesentery (Figure 4a). Thyroid ultrasonography described it within normal limits. Parathyroid hormone was reported at 32.5 pg/mL.

The macroscopic histopathological study recorded the finding of irregular bone fragments that together measured 8 cm. The microscopic findings corresponded to fragments of mature trabecular and medullary bone tissue, mesenchymal metaplasia composed of mature bone tissue, with no atypia or malignancy on examination (Figure 4b).

The patient had an adequate clinical evolution, with adequate tolerance to the oral route, the abdomen was soft and depressible, functional ileostomy with peristalsis present and normal, with no signs of intestinal obstruction, the operative wound with approximated edges, without secretions, due to this, discharge was decided after 79 days of admission with good clinical

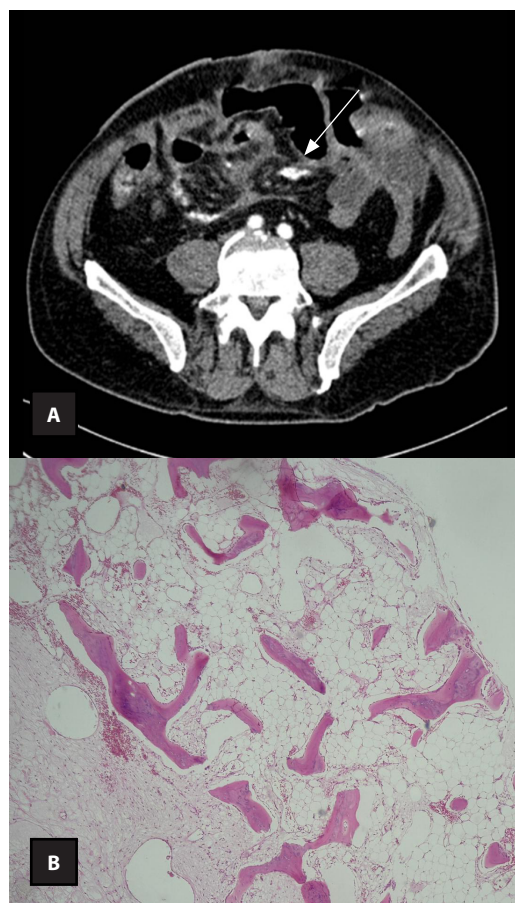


Figure 4. A. Abdominal tomography with heterotopic osteogenesis indicated by arrow. B. Fragments of mature trabecular and medullary bone tissue

condition, with the follow-up plan by the complex abdomen team of the Medical Surgical Hospital (Figure 5).

Clinical diagnosis

Histopathological diagnosis confirms mesenteric heterotopic ossification as the cause of intestinal obstruction following resolution of the enteroatmospheric fistula.

Discussion

Heterotopic osteogenesis is a rare pathology with very few reports;^{vii} currently, there are about 75 cases reported according to searches in EMBASE and PUBMED,^{iii,viii-xii} reviews have found that this entity occurs mostly in patients of middle to late adulthood, with a predominance of male patients.^{xiii} In the majority of patients with

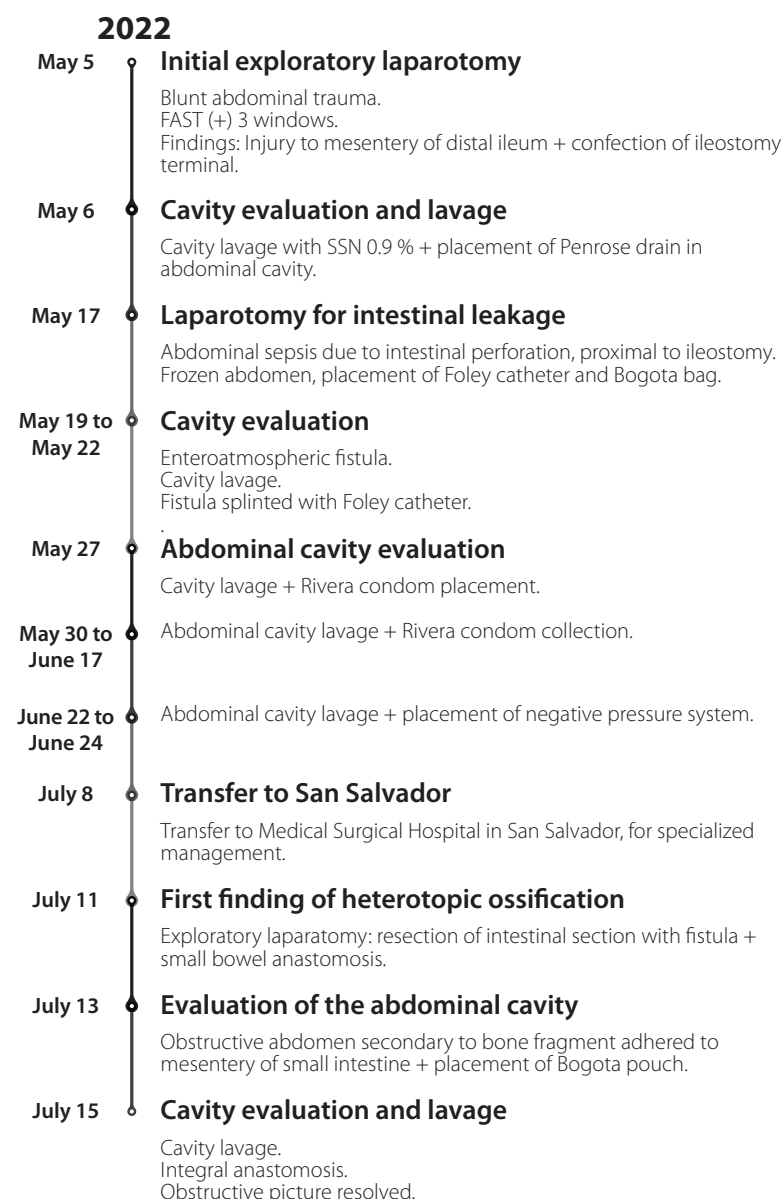


Figure 5. Timeline

septic abdomen who have undergone multiple abdominal surgical interventions,^{xiv} according to the results of pathological studies, the presence of mature bone formations with trabecular structure similar to that of cancellous bone has been determined.^{xv} These findings inside the abdominal cavity being the cause of intestinal obstruction are a rarely described pathology.

The pathophysiology of the formation of this bone tissue in the abdominal cavity is still unknown. It is theorized that heterotopic osteogenesis is due to stimulation of pluripotential mesenchymal stem cells in response to inflammation, causing differentiation of these stem cells into osteoblasts.^{xi} Multiple cases of intestinal obstruction associated with heterotopic ossification have been reported over the years, in addition to other symptomatology, such as early satiety and epigastralgia.^{xvi}

After the removal of this bone structure, the permeability of the intestinal tract was achieved, improving the passage of intestinal contents, which makes this pathology one more complication that a patient who has undergone multiple abdominal surgeries may suffer, as detailed by Althaqafi *et al.* in their review of cases.^{xv}

As detailed in the timeline (Figure 5), the patient's evolution was satisfactory for the resolution of the intestinal obstruction; the symptoms of this entity may not be specific, with vague abdominal symptoms, such as vague abdominal pain, nausea, and vomiting. Due to the limited research on these cases, it is challenging to identify this entity as the root cause of the issue. Typically, the diagnosis is made incidentally. In this case, serial measurements of calcium and parathyroid hormone were conducted, but they did not reveal any alterations, thus preventing any correlation with endocrinological entities to date.

Medical therapies, including bisphosphonates and NSAIDs, may help mitigate recurrence, but further research is needed to determine the efficacy.^{xvii} Some authors have advocated surgical resection, while others suggest that this may induce further heterotopic mesenteric ossification formation.

Heterotopic mesenteric ossification must be considered in those patients in whom mineralization of the mesentery is detected on CT scans, especially if there has been major surgery or previous trauma. As presented in this case, ossification can develop within a few weeks of major surgery and can progress and evolve to form wide or irregular ossification laminae, leading to bowel obstruction and perforation. Radiologists and surgeons must not dismiss

early signs of ossification as surgical or other foreign material to avoid misdiagnosis.^{xii}

Funding

No external funds were available.

References

- i. Choi H, Choi J-W, Ryu DH, Woo CG, Kim KB. Spontaneous heterotopic mesenteric ossification around the pancreas causing duodenal stenosis: A case report with literature review. *International Journal of Surgery Case Reports*. 2021;81:105702. DOI: [10.1016/j.ijscr.2021.105702](https://doi.org/10.1016/j.ijscr.2021.105702)
- ii. Amalfitano M, Fyfe B, Thomas SV, Egan KP, Xu M, Smith AG, *et al.* A case report of mesenteric heterotopic ossification: Histopathologic and genetic findings. *Bone*. 2018;109:56-60. DOI: [10.1016/j.bone.2018.01.006](https://doi.org/10.1016/j.bone.2018.01.006)
- iii. Bahmad HF, Lopez O, Sutherland T, Vinas M, Ben-David K, Howard L, *et al.* Heterotopic mesenteric ossification: a report of two cases. *JPTM*. 2022;56(5):294-300. DOI: [10.4132/jptm.2022.07.23](https://doi.org/10.4132/jptm.2022.07.23)
- iv. Cao G, Zhang S, Wang Y, Quan S, Yue C, Yao J, *et al.* Pathogenesis of acquired heterotopic ossification: Risk factors, cellular mechanisms, and therapeutic implications. *Bone*. 2023;168:116655. DOI: [10.1016/j.bone.2022.116655](https://doi.org/10.1016/j.bone.2022.116655)
- v. Muñoz-Ruiz EO, Bravo-Flórez NM, Herrera Chaparro JA, Vallejo-Vallecilla G. Nueva técnica para control de contaminación de fistulas enteroatmosféricas en abdomen abierto Björck 4. Método de Capilaridad (MECA). *Rev Colomb Cir*. 2021;37(1):90-95. DOI: [10.30944/20117582.939](https://doi.org/10.30944/20117582.939)
- vi. Björck M, Kirkpatrick AW, Cheatham M, Kaplan M, Leppäniemi A, De Waele JJ. Amended Classification of the Open Abdomen. *Scand J Surg*. 2016;105(1):5-10. DOI: [10.1177/1457496916631853](https://doi.org/10.1177/1457496916631853)
- vii. Louis EM, Nicolaou S. Bowel obstruction and perforation secondary to progressive heterotopic mesenteric ossifications. *Radiology Case Reports*. 2022;17(10):3651-3654. DOI: [10.1016/j.radcr.2022.06.010](https://doi.org/10.1016/j.radcr.2022.06.010)
- viii. Andrea Aurelio R, Nicola DR, Stefani C, Francesco S, Alberto F, Anna Vittoria M, *et al.* An unusual case of bowel obstruction in emergency surgery: The heterotopic mesenteric ossification. *SAGE Open Medical Case Reports*. 2020;8:2050313X2092604. DOI: [10.1177/2050313X20926042](https://doi.org/10.1177/2050313X20926042)
- ix. Ferreira C, Gomes C, Melo A, Tenreiro N, Pinto B, Moreira H, *et al.* Heterotopic mesenteric and abdominal wall ossification - Two case reports in one institution.

- International Journal of Surgery Case Reports. 2017;37:22-25. DOI: [10.1016/j.ijscr.2017.06.004](https://doi.org/10.1016/j.ijscr.2017.06.004)
- x. Hansen Ø, Sim F, Marton PF, Grüner O-PN. Heterotopic Ossification of the Intestinal Mesentery. Pathology - Research and Practice. 1983;176(2-4):125-130. DOI: [10.1016/S0344-0338\(83\)80004-1](https://doi.org/10.1016/S0344-0338(83)80004-1)
 - xi. Koolen PGL, Schreinemacher MHF, Peppelenbosch AG. Heterotopic Ossifications in Midline Abdominal Scars: A Critical Review of the Literature. European Journal of Vascular and Endovascular Surgery. 2010;40(2):155-159. DOI: [10.1016/j.ejvs.2010.03.010](https://doi.org/10.1016/j.ejvs.2010.03.010)
 - xii. Navarro-Briceño Y, Villalba-Meneses CP. Osificación heterotópica intraabdominal: reporte de caso. RCHRAD. 2021;27(4):7700. DOI: [10.24875/RCHRAD.M21000012](https://doi.org/10.24875/RCHRAD.M21000012)
 - xiii. Lai H-J, Jao S-W, Lee T-Y, Ou J-J, Kang J-C. Heterotopic Mesenteric Ossification After Total Colectomy for Bleeding Diverticulosis of the Colon—A Rare Case Report. Journal of the Formosan Medical Association. 2007;106(2):S32-S36. DOI: [10.1016/S0929-6646\(09\)60350-8](https://doi.org/10.1016/S0929-6646(09)60350-8)
 - xiv. Çelik SU. Heterotopic mesenteric and omental ossification incidentally found in a patient with multiple abdominal surgical operations because of gunshot injury. Ulus Travma Acil Cerrahi Derg. 2018. DOI: [10.5505/tjtes.2018.44014](https://doi.org/10.5505/tjtes.2018.44014)
 - xv. Althaqafi RMM, Assiri SA, Aloufi RA, Althobaiti F, Althobaiti B, Al Adwani M. A case report and literature review of heterotopic mesenteric ossification. International Journal of Surgery Case Reports. 2021;82:105905. DOI: [10.1016/j.ijscr.2021.105905](https://doi.org/10.1016/j.ijscr.2021.105905)
 - xvi. Oroian T. S2994 History of Parachuting as Cause of Heterotopic Mesenteric Ossification in an Elderly Male. Am J Gastroenterol. 2021;116(1):S1239-S1240. DOI: [10.14309/01.ajg.0000785508.41498.e8](https://doi.org/10.14309/01.ajg.0000785508.41498.e8)
 - xvii. Honjo H, Kumagai Y, Ishiguro T, Imaizumi H, Ono T, Suzuki O, *et al.* Heterotopic Mesenteric Ossification After a Ruptured Abdominal Aortic Aneurism: Case Report With a Review of Literatures. International Surgery. 2014;99(4):479-484. DOI: [10.9738/INTSURG-D-13-00074.1](https://doi.org/10.9738/INTSURG-D-13-00074.1)